

PERCEPTION OF THE MOST ESTHETICALLY PLEASING INCISAL EMBRASURE DESIGN

Amna Badshah¹, Mariya Khalid²

ABSTRACT

OBJECTIVES

To determine the frequency of female dentate patients' most appealing incisal edge embrasure designs.

METHODOLOGY

The sample consisted of 385 female dentate patients between 18 to 40 years of age visiting Sardar Begum Dental College and Hospital, Peshawar, from January 2021 to June 2021. The subject's perception was recorded by having the subjects visualize a set of five photographs showing different categories of incisal edge embrasure designs classified by Foulger and Tredwin. The labels of these different photograph categories were obscured using a non-transparent tape, and A, B, C, D, and E; names were assigned to them, respectively, to avoid bias. Means and standard deviations were calculated for quantitative variables like age, while the frequency was calculated in percentage for categorical variables for the most appealing incisal edge embrasure design.

RESULTS

The most attractive incisal edge embrasure design amongst the female dentate patients was the "Ideal" design with 33.8%. The second most attractive design displayed "Equal" incisal edge embrasures with 31.4. The "Reversed" and "None" categories had 12.2% and 9.9% percentages. The least attractive design amongst these females was with "Exaggerated" incisal edge embrasures.

CONCLUSION

Female dentate patient's most appealing incisal edge embrasure design displays the "Ideal" incisal edge embrasure form.

KEYWORDS: Esthetics, Incisal Edge Embrasure, Perception, Smile

How to cite this article:

Badshah A, Khalid M. Perception of the Most Esthetically Pleasing Incisal Embrasure Design. J Gandhara Med Dent Sci. 2022;9(3): 51-56
<https://doi.org/10.37762/jgmids.9-3.292>

Correspondence

¹Amna Badshah, FCPS Post Graduate Resident
Prosthodontics, Sardar Begum Dental College & Hospital
☎: +92-333-883448
✉: aamna139badshah@gmail.com
²Assistant Professor, Sardar Begum Dental College & Hospital

INTRODUCTION

To a greater extent, the dominant motivation for treatment has been dentofacial appearance rather

than improved dental health and function.¹ In today's society, beauty and attractiveness are very well established. However, what leads to the incomplete service of patients and frustration on the part of the practitioners, is not being able to incorporate visually essential aspects of dental anatomy into esthetic restorations.² Smile is an important facial expression which is essential to the expression of emotions.³ Although the tooth is considered to be the basic component of smile design, the "incisal embrasure's" role cannot be overlooked as a smile is more considerably affected

by a small change in the embrasures rather than the change in the tooth anatomy itself.⁴ Teeth shapes play an important role in esthetics and influence the pattern of the incisal embrasure.⁵ Incisal embrasure is the divergence formed by the proximal surfaces of anterior teeth from the contact point initially. From the central incisors to the canines, there should be a natural and gradual increase in the depth of the incisal embrasures. Also, it is the primary function of the anatomy of these teeth that between the maxillary central incisors, the central and the lateral incisors and the lateral incisors and the canines, the incisal edge embrasure space should get larger and progressively increase in volume distally.⁶ In a study conducted by Mainak Kanti Saha and Margie Khatir, the contact dimensions between the central incisors, the central and lateral incisors and the lateral incisor and canine was consistent with the fact that the incisal embrasure dimensions increase progressively from the midline to the canine. The study evaluating the influence of the incisal edge embrasure space and interproximal tooth contact point on smile esthetics revealed that the most popular incisal edge embrasure space arrangement was the one that showed a progressive increase of the embrasure spaces distally from the central incisors, preferred by 49.5% of the participants, next on the list was the design in which minimal embrasure spaces were displayed, selected by 33% of the candidates. The least attractive arrangement was where embrasure spaces were totally absent, which 27.6% preferred.⁷ An individual's age is also expressed by the central incisors as the incisal edges in youthful teeth are unworn and have a very well-defined incisal embrasure. In a case study carried out in 2016, in a young patient with bruxism, a progressive increase in the size and depth of incisal embrasures resulted in a pleasing smile.⁸ In older dentition, the incisal edges get blunt with wear and attrition; a younger smile can be given by altering the incisal embrasure forms.⁹ Contact points and incisal embrasures are also carefully planned while rehabilitating smiles using direct composite restorations because of their significant influence.¹⁰ The perception of tooth size is also altered by the shape of the embrasure, teeth with large embrasures look smaller, and those teeth appear larger with small embrasures.^{11, 12} Achieving proper function and esthetics ensures success in prosthodontics and aesthetic restorative dentistry. For efficient mastication, the incisal embrasures are relevant, and to the anterior dentition, they give individuality.¹³ The use of digitally altered pictures helps evaluate a single aspect more accurately as the confounding factors are removed by altering

only the feature of interest in a picture and keeping the other features constant.¹⁴ Perception of different components of smile esthetics is greatly influenced by differences in demographics, race, ethnicity, and culture.¹⁵ In this study, we aimed to find the most appealing incisal edge embrasure design in female dentate patients reporting to Sardar Begum Dental Hospital; as such, a study hasn't been carried out locally, i.e., in the population of Khyber Pakhtunkhwa before. Thus, the results of this study lead us to the popular perception of incisal edge embrasures among females of Khyber Pakhtunkhwa. The study results can be helpful for prosthodontists to direct their dental laboratories to keep the most popular design before them while fabricating veneers and anterior crowns for female patients and thus meet the patient's perceptions.

METHODOLOGY

This cross-sectional study was conducted in a period of 6 months from January 2021 to June 2021 in Prosthodontics Department, Sardar Begum Dental College and Hospital, Peshawar after approval from ethical committee of the institute. Sample size was 385 dentate female patients calculated by the formula,

$n = z^2 p (1 - p) / d^2$, where,

n = Sample Size, Z = (1.96 for a level of confidence of 95%) P = Estimated proportion of the population that presents the characteristic. The value is 49.5%¹ ~ 50%, thus $P = 0.5$ D = Margin of error = 0.05

Sample Size = $(1.96)^2 (0.5) (1-0.5) / (0.05)^2$

$n = (3.8416) (0.25) / 0.0025$

$n = 0.9604 / 0.0025$

Thus, Sample size = 385

The sampling technique was non-probability Convenience sampling. Female dentate subjects visiting the dental OPD of Sardar Begum Dental College and Hospital, Peshawar, between the age of 18 and 40 years, were included in the study. Mentally handicapped subjects and patients with blindness/visual problems were excluded. The purpose, procedure and benefits of the study were explained to them and informed written consent was obtained, ensuring the confidentiality of the study.

Ideal Incisal Edge Embrasure Design

The ideal embrasure design is considered one which fulfills the 50-40-30 rule¹.

50-40-30 Rule

The ideal contact area between the two central incisors is 50% of the length of the crowns between the maxillary central and lateral incisor, it is 40% of the crown of the central incisor and between the

lateral incisor and canine is 30% the length of the central incisor crown.¹

Most Appealing Incisal Edge Embrasure Design:

The incisal edge embrasure design is the most pleasing to and preferred by the female dentate subjects of Sardar Begum Dental College and Hospital, Peshawar. The study was carried out in a well-lit room and with a separate dental chair to avoid distractions. The subject's perception was recorded by having the subjects visualize a set of five photographs showing different categories of incisal edge embrasure designs classified by Foulger and Tredwin.¹ These five photographs were given in the Data Collection Questionnaire showing the categories "ideal", "none", "equal", "exaggerated", and "reversed". The labels of these different categories were obscured using a non-transparent tape, and the letters of the alphabet, i.e. A, B, C, D, E; names were assigned to them respectively to avoid bias. One standard image (Figure 1:) was shown to all the subjects, and only one operator conducted the study to eliminate the possibility of bias. The data analysis procedure was done using version 21 of SPSS software. Means and standard deviations were calculated for quantitative variables like age, while the frequency was calculated in percentage for categorical variables for the most appealing incisal edge embrasure design.

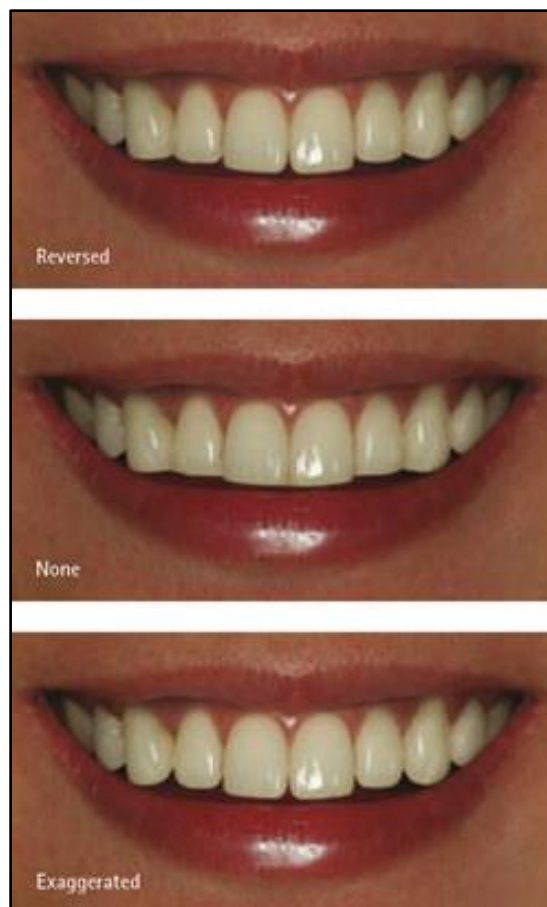
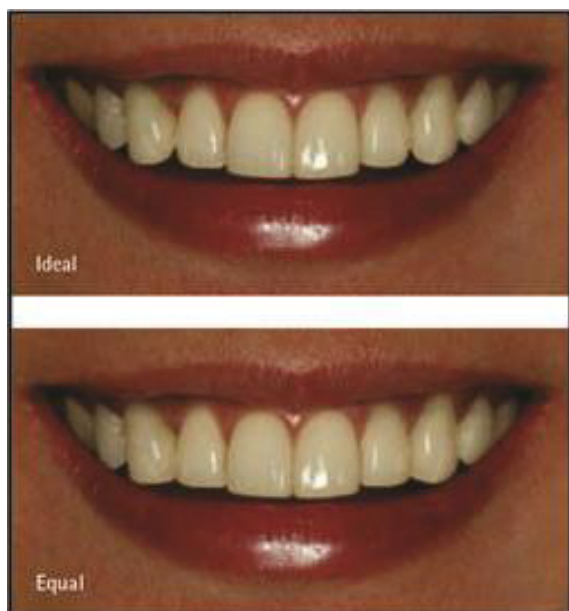


Figure No 1: "Ideal", "None", "Equal", "Exaggerated", "Reversed" Incisal Edge Embrasures Designs¹ Have Been Assigned The Names A, B, C, D And E, Respectively. These Labels are Obscured from the Subject's Sight with a Non-Transparent Tape.

RESULTS

The total sample size was 385, divided into two age groups for convenience and ease of entry into the SPSS software. The first age group had female subjects between 18 and 29 years, while the second group had subjects between 30 and 40. 65.7% of the patients were between 18- 20 years of age, while 34.3% were between 30-40 years. The most appealing design out of the five incisal edge embrasure modifications was the image (A), i.e., the smile with an ideal design. The second most attractive design was an image (B), i.e., the smile with equal incisal edge embrasures. Surprisingly, our female subjects perceived the third most attractive smile displayed reversed incisal edge embrasures. So, the most appealing incisal edge embrasure design based on the images selected by the subjects in descending order are Ideal incisal edge embrasures > Equal incisal edge embrasures > Reversed incisal edge embrasures.

Table 1: Frequency of Most Esthetically Pleasing Incisal Embrasure Designs Selected by Patients.

Incisal Edge Embrasure Design	Frequency	Percentage
Ideal	130	33.8
Equal	121	31.4
Reversed	47	12.2
None	49	12.7
Exaggerated	38	9.9
Total	385	100

A slight variation in the results was found when each age group was assessed individually. Age group A, i.e., female subjects from 18 to 29, found the equal incisal edge embrasure design to be the most appealing.

Table 2: Frequency of Most Esthetically Pleasing Incisal Embrasure Designs Selected By Patients Between 18 -29 Years of Age.

Incisal Edge Embrasure Design	Frequency	Percentage
Ideal	82	32.4
Equal	85	33.6
Reversed	25	9.9
None	34	13.4
Exaggerated	27	10.7
Total	253	100.0

In age group B, i.e., female subjects aged 30 to 40 found the ideal incisal edge embrasure design to be the most appealing. The results of this particular Age Group were thus the same as the study's overall results when no two groups were analyzed separately.

Table 3: Frequency of Most Esthetically Pleasing Incisal Embrasure Designs Selected by Patients between 30-40 Years of Age.

Incisal Edge Embrasure Design	Frequency	Percentage
Ideal	48	36.4
Equal	36	27.3
Reversed	22	16.7
None	15	21.4
Exaggerated	11	8.3
Total	132	100.0

DISCUSSION

While the parameters constituting the optimal esthetics are obvious to the dentist, there is a lot of disagreement among people regarding their individual preferences. These individual preferences are based on various variables of education, social circle and social awareness, the nature of the job, and the gender of the particular person.¹⁶ Incisal embrasures play a significant role in individualizing smiles as altering depth and angulation can give a younger or mature person an illusion. The literature contains many studies that evaluate people's perception regarding different components of the smile, in this particular case, the incisal edge embrasures. Also, studies have concluded a vast

difference in the perception of males and females, where males usually found squarish box-like incisal embrasures appealing, while females chose the design with a softer and rounder incisal edge embrasure forms. No study has been conducted to address female dentate subjects aged 18-40 years, the age of serious esthetic concern.¹⁷ This study evaluated the esthetic perception of dentate female subjects and found that most of them perceived the smile incorporating the ideal incisal edge embrasure design to be the most attractive and pleasant. This meant that the individual perception of the majority of females regarding "beauty and esthetics" agreed with the common understanding of dental professionals, i.e., they chose the design with the ideal embrasure form, following the 50:30:40 rule displaying a gradual increase from the midline to the distal.¹⁸ Another study was conducted to evaluate the perception of laypersons, general dentists, and orthodontists and orthodontic patients regarding esthetically pleasing incisal embrasures; the study results showed that generally, semi-round form in incisal embrasure was preferred by both males and females in all groups.⁵ However, the limitation of the study was that only three forms of incisal embrasures were studied with varying amounts of the gingival display. Five forms of incisal embrasures were studied in this study while keeping the other parameters constant to remove confounders. According to our study, the patients preferred the semi-round form's ideal embrasure form. The digital variations of the standard image were used for this study, having the same gingival display. A smile involving only the lower third of the face was used in this study to avoid distractions by other parameters like soft tissue profile, face symmetry and face shape over the esthetic judgment of the patient and to focus better on the tooth component in this case, the incisal edge embrasure in specific. Another study evaluated the proximal contact area in anterior maxillary teeth and found that this area gradually decreases anteroposteriorly in both males and females; this can be interpreted as an increase in incisal embrasure from anteroposteriorly.¹⁷ In our study population, most participants opted for the ideal incisal embrasure form as most esthetically pleasing as this is present naturally. However, the second most esthetically pleasing incisal form selected was smiled with equal incisal embrasures anteroposteriorly; this can be because laypersons perceive teeth with equal embrasures to be better aligned. According to a systematic review, the most attractive incisor embrasure patterns perceived by laypersons were when embrasures are equal and when embrasures

increase distally. This study, too, gave the same results.¹⁸ For future studies, such consideration is recommended for finding an association and correlation between the ideal incisal edge embrasure and the particular facial form or profile of a person and how it affects the final esthetic preference. One study compared the incisal edge embrasures of natural dentition and prosthetically restored anterior maxillary teeth. They found the prosthetic crowns and artificial teeth to have a more unnatural and monotonous appearance due to ignoring the embrasure form and its incorporation into the restoration.¹⁹ The dental laboratory would benefit from the results of this study that found three main incisal edge embrasure forms that appealed to the female patients, i.e., the reverse, the equal and the ideal incisal embrasure form in increasing order of preference. Good communication between the dentist and patient and referral of the patient's esthetic preference to the laboratory can lead to a successful outcome in treatment and meeting the patient's specific demands.

LIMITATIONS

The current study used an image that originally had a squarish incisal edge embrasure form, which was then digitally altered into five categories. The fact that only a single female's smile, with a squarish incisal embrasure form, was digitally altered has influenced the overall outcome of the perception of these female subjects and has restricted it to the domain of one particular embrasure form. This is the limitation of this study. For future studies, a recommendation for using images of female models with different incisal edge embrasure forms of "round", "semi-round", and "squarish" is proposed. These embrasure forms can then be digitally altered into five different categories, thus giving the female subjects a wider range of embrasure form variations. Another limitation of this study is that it focuses on the female gender and a particular age group.

CONCLUSION

This study concludes that the design that appeals the most to female dentate subjects is the ideal incisal edge embrasure design, which follows the 50-40-30 rule. This rule suggests a gradually progressive increase in the incisal edge embrasure space from the midline towards the distal area, and the most popular perception of this age group of females agrees with that. This result will be communicated to other dental institutions of Khyber Pakhtunkhwa so that their dental practitioners and laboratories keep this most popular design before them while

fabricating dental prostheses for the anterior esthetic zone, such as veneers, crowns, fixed partial prostheses etc. in female patients, thus meeting the requirements of their liking and perception.

CONFLICT OF INTEREST: None

FUNDING SOURCES: None

REFERENCES

1. Foulger TE, Tredwin CJ, Gill DS, Moles DR. The influence of varying maxillary incisal edge embrasure space and interproximal contact area dimensions on perceived smile aesthetics. *Br Dent J* [Internet]. 2010;209(3):E4.
2. Duarte MEA, Machado RM, Da Motta AF, Mucha JN, Motta AT. Morphological Simulation of Different Incisal Embrasures: Perception of Laypersons, Orthodontic Patients, General Dentists and Orthodontists. *J Esther Restor Dent*. 2017;68–78.
3. Al-Saleh SA, Al-Shammery DA, Al-Shehri NA, Al-Madi EM. Awareness of Dental Esthetic Standards Among Dental Students and Professionals. *Clin Cosmet Investig Dent*. Vol. 11. Page; 2019.
4. Ribeiro JB, Machado FBA. Does the presence of unilateral maxillary incisor edge asymmetries influence the perception of smile esthetics? *J Esther Restor Dent*. 2017;29:291–7.
5. Eduarda Assad Duarte M, Martins Machado R, Fonseca Jardim da Motta A, Nelson Mucha J, Trindade Motta A. Morphological simulation of different incisal embrasures: Perception of laypersons, orthodontic patients, general dentists and orthodontists: Morphological simulation of different incisal embrasures. *J Esthet Restor Dent* [Internet]. 2017;29(1):68–78.
6. Levine JB, Finkel S. Esthetic diagnosis: a three-step analysis. *Smile Design Integrating Esthetics and Function: Essentials in Esthetic Dentistry*. 2016;2:1–42
7. Saha MK, Khatri M, Saha SG, Dubey S, Saxena D, Vijaywargiya N, et al. perception of acceptable range of smiles by specialists, general dentists and lay persons and evaluation of different aesthetic paradigms. *J Clin Diagn Res* [Internet].

- 2017;11(2):ZC25–8.
8. Da Nóbrega Dias J, Veras IM, Barbosa GA, De Assunção IV. Reverse planning for making an occlusal splint before restorative treatment: case report of rehabilitation of a patient with bruxism. *Research, Society and Development*. 2020;9.
 9. Paken G, Ünal M. Evaluation of perceptions of smile esthetics by dental students. *Balkan J Dent Med* [Internet]. 2021;25(3):100–7.
 10. Bassett J. Applying classical esthetic principles to create a predictable illusion of symmetry while using digital technology. *Compend Contin Educ Dent*. 2020;41(4):204–9; quiz 210.
 11. Kau CH, Christou T, Xie RB, Abou-Saleh T. Rating of smile attractiveness of patients finished to the American Board of Orthodontics standards. *J Orofac Orthop* [Internet]. 2020;81(4):239–48.
 12. Vargas MA, Margeas R. A systematic-approach to contouring and polishing anterior resin composite restorations: A checklist manifesto. *J Esthet Restor Dent* [Internet]. 2021;33(1):20–6.
 13. Chen Y-H, Cheng Y-L, Cheng H, Yu H. Comparison of smile esthetics among celebrities, dentists, and dental students in a Han Chinese population. *J Prosthet Dent* [Internet]. 2020;123(6):845–9.
 14. Nomura S, Freitas KMS, Silva PPC da, Valarelli FP, Cañado RH, Freitas MR de, et al. Evaluation of the attractiveness of different gingival zeniths in smile esthetics. *Dental Press J Orthod* [Internet]. 2018;23(5):47–57.
 15. Wang C, Hu W-J, Liang L-Z, Zhang Y-L, Chung K-H. Esthetics and smile-related characteristics assessed by laypersons. *J Esthet Restor Dent* [Internet]. 2018;30(2):136–45.
 16. Kallala R, Nasri S, Adli A, Baccouche C, Touzi S, Hadyaoui D, et al. A Morphological Respected Rehabilitation of Maxillary Central Incisor: A Clinical Report.
 17. Oliveira PLE, Motta A, Pithon M, Mucha J. Details of pleasing smiles. *Int J Esthet Dent*. 2018;13(4):494–514.
 18. Kolte AP, Kolte RA, Bawankar P. Proximal contact areas of maxillary anterior teeth and their influence on interdental papilla. *Saudi Dent J* [Internet]. 2018;30(4):324–9.
 19. Del Monte S, Afrashtehfar KI, Emami E, Abi Nader S, Tamimi F. Lay preferences for dentogingival esthetic parameters: A systematic review. *J Prosthet Dent* [Internet]. 2017;118(6):717–24.

CONTRIBUTORS

1. **Amna Badshah** - Concept & Design; Data Acquisition; Data Analysis / Interpretation; Drafting Manuscript
2. **Mariya Khalid** - Concept & Design; Critical Revision; Supervision; Final Approval



LICENSE: JGMDS publishes its articles under a Creative Commons Attribution Non-Commercial Share-Alike license (CC-BY-NC-SA 4.0).

COPYRIGHTS: Authors retain the rights without any restrictions to freely download, print, share and disseminate the article for any lawful purpose. It includes scholarly networks such as Research Gate, Google Scholar, LinkedIn, Academia.edu, Twitter, and other academic or professional networking sites.