

ANATOMICAL VARIATIONS OF EXTRAHEPATIC BILIARY TRACT AND RELATED VESSELS DURING LAPAROSCOPIC CHOLECYSTECTOMY

Muhammad Bilawal Khan¹, Muhammad Iftikhar², Siddique Ahmad³

How to cite this article

Khan MB, Iftikhar M, Ahmad S.
Anatomical Variations of Extrahepatic
Biliary Tract and Related Vessels
during Laparoscopic Cholecystectomy.
J Gandhara Med Dent Sci. 2025; 12(1):
3-6.doi:10.37762/jgm.12-1.623

Date Submission: 10-09-2024

Date Revised: 06-11-2024

Date Acceptance: 19-11-2024

¹Specialist Registrar, Hayatabad
Medical Complex Peshawar

³Professor Department of Surgical “C”
Unit, Hayatabad Medical Complex
Peshawar

Correspondence

²Muhammad Iftikhar, Associate
Professor, Department of General
Surgery, Hayatabad Medical Complex
Peshawar

☎: +92-333-9177399

✉: iffi_khattak@hotmail.com

ABSTRACT

OBJECTIVES

This study aims to add to the existing knowledge by evaluating the frequency of usual pathologies in the biliary system and blood vessels observed during Laparoscopic cholecystectomy.

METHODOLOGY

This cross-sectional study was conducted at the General Surgery Department of Hayatabad Medical Complex, Peshawar, from November 2022 to November 2023. The study comprised 65 patients aged 18-50 with known cases of cholelithiasis. Exclusion criteria included patients with empyema gallbladder, gallbladder carcinoma, and a history of diabetes mellitus or hypertension.

RESULTS

The mean age of patients was 40.1±3.95 years, with females comprising 64.6% and males comprising 35.4% of the sample. Overall, extrahepatic biliary tract anomalies were found in 24.6% of cases. The incidence of anatomic variations in the present study was as follows; a short cystic duct was the most frequent variation observed in the present study and was found in 9.2%, followed by a long cystic duct (7.7%), duct of Luschka, and Moynihan hump anomaly (3.1% each).

CONCLUSION

Out of all the parameters, short cystic duct predominated, emphasizing the significance of a perfect surgical approach. The fact that anomalies are distributed equally across the various demographics underlines their inherent attributes. These findings call for further research that will enhance the performance of surgeries and the benefits of laparoscopic cholecystectomy treatments.

KEYWORDS: Laparoscopic Cholecystectomy, Anatomical Variations, Biliary Tract Anomalies, Surgical Outcomes, Gallstone Disease

INTRODUCTION

Gallstone disease is still a significant health problem worldwide, as more than one-third of the adult population has gallstones. Since its introduction, laparoscopic cholecystectomy (LC) has become the gold-standard treatment for symptomatic gallstone diseases.¹ It has shown rapid worldwide acceptance because it is minimally invasive, with a success rate of over 95 % in treating benign conditions. Nevertheless, the outcome of this surgical measure is highly dependent on knowledge about anatomical variations and potential anomalies likely to be encountered during surgery.³ The extrahepatic biliary tract has a complex anatomy known to be variable, and variations are described in the literature.⁴ These variations are anatomic anomalies like long cystic duct, short cystic duct, bile leakage due to the accessory duct (Luschka), and vascular anomalies like aberrant cystic artery. Surgeons must recognize and understand these

anomalies to maneuver through the biliary system.⁵ Short cystic ducts are known to be associated with a high grade of difficulty during cholecystectomy procedure, making meticulous dissection crucial in avoiding iatrogenic injury.⁶ On the contrary, long cystic ducts are less commonly observed, so customized surgical approaches should be taken to accommodate that issue and better clinical outcomes.⁷ In addition, the presence of ducts of Luschka and a Moynihan hump (a peculiar “humped” cystic duct) poses surgical challenges.^{8,9,10} In addition, the accessory cystic artery should be carefully preserved to avoid iatrogenic injuries while dissecting Calot’s triangle.¹⁰ While existing literature has explored these anomalies individually, there is a paucity of comprehensive studies investigating their collective frequency within a specific patient population. Through meticulously analyzing demographic data and stratified examinations, our study seeks to elucidate potential associations between these anomalies and age, gender,

and other relevant factors. Furthermore, this research endeavors to enhance understanding of common extrahepatic biliary tract and vascular anomalies, refining surgical techniques and optimizing patient outcomes in laparoscopic cholecystectomy.

METHODOLOGY

This Cross-sectional study was carried out at the General Surgery Department, Hayatabad Medical Complex Peshawar, from November 2022 till November 2023. A total of 65 patients were included in the study. Patients of both genders, ages 18-50 years, and diagnosed cases of cholelithiasis on ultrasound were included in the study. Patients with empyema gallbladder, carcinoma gallbladder, history of diabetes mellitus, and hypertension were excluded from the study. The purpose and benefits of the study were explained to patients, and proper written informed consent was obtained. All patients who met inclusion criteria were assessed in detail by taking adequate history, conducting a clinical examination, and conducting a routine investigation. History was taken regarding age, gender, diabetes mellitus, and hypertension. Height and weight were measured, and BMI was calculated. In Laparoscopic cholecystectomy, attention was given to anomalies. Under general anesthesia, all the surgeries were performed by the same surgeon and using the same technique of critical view of safety for laparoscopic cholecystectomy. Data was collected using structured proforma. All the data analysis was done in Statistical Package for Social Sciences (SPSS) version 25.0. Frequency and percentages were calculated for gender, extrahepatic biliary tract, and vascular anomalies. Mean ± Standard deviation was computed for numerical variables like age, height, weight, and BMI. Anomalies were stratified in age and gender distribution. Post-stratification, a chi-square test was used. A p-value of less than 0.05 was considered as significant. All the research was presented in the form of tables and charts.

RESULTS

The mean age of patients was 40.1±3.95 years. Females comprised 64.6% of the study sample. The mean BMI was 31.5±3.76 kg/m². Overall, 16 patients (24.6%) had anatomical anomalies of the extrahepatic biliary tract and related vessels.

Table 1: Enlisting Characteristics of Patients with Placenta Previa

Demographics	Mean ± SD
Age (years)	40.107±3.95
Weight (Kg)	82.153±5.34
Height (m)	1.620±0.07
BMI (Kg/m ²)	31.528±3.76

Abnormal anatomy of the extrahepatic biliary tract was found to be 16(24.6%), amongst which the most common one was short cystic duct 6 (9.2%), followed by long cystic duct 5 (7.7%), duct of Luschka and Moynihan hump anomaly 2 (3.1%) cases each and accessory cystic artery was the least common anomaly, seen in only 1 (1.5%) patient respectively.

Table 2: Frequency of Different Anomalies

Anomaly	Frequency	%age
Short cystic duct	06	9.2
Long cystic duct	05	7.7
Luschka	02	3.1
Moynihan hump	02	3.1
Accessory cystic artery	01	1.5

Stratification of anomalies by age and gender showed no statistically significant association.

Table 3: Stratification of Anomalies to Gender

Gender	Long Cystic duct	Short Cystic duct	Duct of Luschka	Moynih anhump	Accessory Cystic artery
Male	02(8.7%)	04(17.4%)	0(0%)	0(0%)	0(0%)
Female	03(7.1%)	02(4.8%)	02(4.8%)	02(4.8%)	01(2.4%)
P-Values	0.822	0.093	0.288	0.288	0.456

Table 4: Stratification of Anomalies to Age (Years)

Age (years)	Long Cystic duct	Short cystic duct	Duct of Luschka	Moynihan hump	Accessory cystic artery
18-35	0(0%)	1(10%)	0(0%)	1(10%)	0(0%)
36-50	5(9.1%)	5(9.1%)	2(3.6%)	1(1.8%)	1(1.8%)
P-Values	0.321	0.927	0.540	0.168	0.667

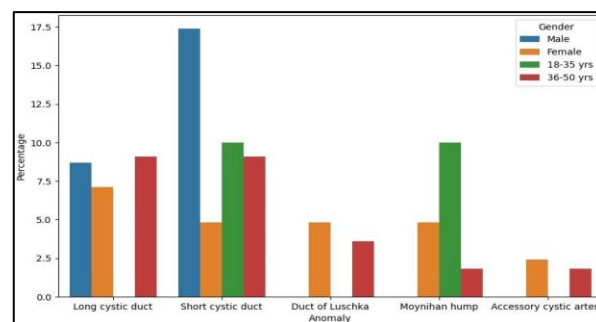


Figure 1: Stratification of Anomalies for Gender and Age Groups

DISCUSSION

The present study delves into the frequency of common extrahepatic biliary tract and vascular anomalies in patients undergoing laparoscopic cholecystectomy, shedding light on the prevalence and characteristics of anatomical variations.¹¹ These findings hold significance in surgical planning, intraoperative decision-making, and postoperative outcomes. The demographic profile of our study cohort revealed a mean age of 40.1±3.95 years, with a predominant

female representation of 64.6%. This is not surprising in that gallstone disease has a long-recognized association with the female gender, and hormonal issues are known to impact the higher prevalence of gallstones among women.¹² We also find a positive relation between obesity and gallstone formation with a mean BMI of 31.5 ± 3.76 kg/m². This was consistent with published literature.^{13,14} Extrahepatic bile ducts and blood vessel anomalies were found in 24.6% of the patients within our series, ranging from “normal appearance” to very complex structural malformations. The most common anomaly noted in 9.2% was the presence of a short cystic duct, followed by long CD (7.7%), Moynihan hump, and Duct of Luschka anomalies were observed at a frequency rate of 3% each. Accessory cystic artery was the anomaly that was observed to be the most uncommon (1.5 % of patients). It stresses that all the surgeons doing laparoscopic cholecystectomy must be vigilant about their existence as they can pose a challenge for Lap Cholecystectomy. The absence of statistical significance for age or gender in the present study may indicate that these variants are distributed uniformly across demographics. This supports the multifactorial origin of gallstone disease and suggests that the spectrum of anatomic abnormality is too heterogeneous to show any age or gender specificity. The incidence of the short cystic duct (9.2%) is consistent with reported rates ranging between 6 and 11% in other studies.¹⁵ The long cystic duct was identified with a frequency of 7.7%, consistent with previously reported, proving the increased compilation data on this infrequent anomaly.¹⁶ Finally, a rare anomaly, i-e, accessory cystic artery (1.5%), this study reinforces the need for careful and meticulous dissection in exploring Calot’s triangle.¹⁷ A stratification by age and gender revealed that this is probably the only way of distribution, as no statistically significant associations could be demonstrated. This finding is consistent with current literature, which suggests that structural variants of the pyramids in patients are constitutive rather than dependent on age or sex. The results of our study add to the literature about age, sex, and biliary anomalies.¹⁸ In line with our findings, multiple authors, in their studies of biliary variations, did not find any age or gender predilections. This uniformity in the discrepancies of different anatomical features across various demographics confirms that these differences are ingrained in all humans.

LIMITATIONS

Although our study provides valuable insights, limitations still need to be addressed. Our study has limitations: a) our investigation was performed at only

one center, and b) the “n” of 65 is a small sample size and could limit our statistical power to estimate efficacy accurately. A more extensive and multicenter study may enhance the external validity of our results. Consequently, although we did not report on the surgical implications of these findings in our research precisely because it was outside its scope (mainly looking at characteristic frequencies), this limitation may need to be addressed. The clinical impact of these anatomical nuances can now be explored in a further study, such as laparoscopic cholecystectomy.

CONCLUSIONS

The present observational cohort study highlights the incidence and features of various common anomalies affecting the extrahepatic biliary tract during laparoscopic cholecystectomy. The most common anomaly was a short cystic duct, which underlines the importance of good surgical anatomy. The fact that these anomalies live amongst various demographic groups paints the picture egregiously. Despite being essential and informative, these findings support a more significant research trajectory toward implementing specific surgical techniques to improve outcomes in laparoscopic cholecystectomy procedures.

CONFLICT OF INTEREST: None

FUNDING SOURCES: None

REFERENCES

- Jarrar MS, Masmoudi M, Mraidha MH, Naouar N, Barka M, Youssef S, et al. Anatomic variations of the upper biliary confluence and intra-hepatic ducts in East-central Tunisian population. *Ital J Anat Embryol.* 2019;124(3): 487-98.
- Pinal-garcia DF, Nuno-guzman CM, Gonzalez-gon-zalez ME. The Celiac Trunk and Its Anatomical Variations : A Cadaveric Study. 2018;10(4):321-9
- Ogut E, Yildirim FB, Memis O: Duplicated gallbladder with acute cholecystitis: a case of unusual presentation and diagnostic challenges. *World J Emerg Med.* 2024, 15:156-8. doi:10.5847/wjem.j.1920-8642.2024.021
- Zhu AY, Seyfi D, Sandroussi C, Abeyasinghe JD: Aberrant vascular anatomy during laparoscopic cholecystectomy: a case report of double cystic artery. *CRSLS.* 2023, 10:e2023.00038. doi:10.4293/CRSLS.2023.00038.
- Jarrar MS, Fourati A, Fadhil H, Youssef S, Mahjoub M, Khouadja H, et al. Risk factors of conversion in laparoscopic cholecystectomies for lithiasic acute cholecystitis. Results of a monocentric study and review of the literature. *Tunis Med.* 2019;97(2): 344-51
- Abdulrasool H, Briggs C: Anatomical variation of arterial blood supply of liver segment IV. *Eur J Anat.* 2018, 22:375-7.
- Gupta R, Kumar A, Hariprasad CP, Kumar M. Anatomical variations of cystic artery, cystic duct, and gall bladder and their associated intraoperative and postoperative complications: an observational study. *Ann Med Surg (Lond).* 2023 Jul 10;85(8):3880-3886. doi: 10.1097/MS9.0000000000001079. PMID: 37554913; PMCID: PMC10406088.

8. Grifson JJ, Perungo T, Sengamalai D, Duraisamy B, Anbalagan A, Raju P, Kannan DG: Anomalous middle hepatic artery in laparoscopic cholecystectomy: wolf in sheep's clothing. *J Minim Access Surg.* 2017, 13:76-7. doi:10.4103/0972-9941.181383
9. Kim SH, Park S, Choi J: A cystic artery arising from the middle hepatic artery detected during laparoscopic cholecystectomy: a case report. *J Surg Case Rep.* 2022, 2022:rjab088. doi:10.1093/jscr/rjab088
10. Gupta V: How to achieve the critical view of safety for safe laparoscopic cholecystectomy: technical aspects. *Ann Hepatobiliary Pancreat Surg.* 2023, 27:201-10. doi:10.14701/ahbps.22-064
11. Boghdady ME, Arang H, Ewalds-Kvist BM: Fundus-first laparoscopic cholecystectomy for complex gallbladders: a systematic review. *Health Sci Rev.* 2022, 2:581-4. doi:10.1016/j.hsr.2022.100014
12. Mlakar B, Gadzijev EM, Ravnik D, et al. . Anatomical variations of the cystic artery. *Eur J Morphol* 2003;41:31-34.
13. Fernandez Trokhimtchouk T, Flores LF, Morillo Cox Á, Otanez ES, Negrete JR, Ayala AV. Unusual Anatomic Variant of the Biliary Tree. *Cureus.* 2023 Oct 17;15(10):e47206. doi: 10.7759/cureus.47206. PMID: 38021781; PMCID: PMC10653010.
14. Halpern SA, Patrizio HA, Brace EJ, Wang S, Yuh JY, Patel DV, Morrison RG, Hall AJ, Falciani A, Deiling KA, Brolis NV. Anatomical Considerations for Gallbladder Sonography: A Cross-Sectional Study of CT Imaging by BMI Group. *Cureus.* 2023 Jun 17;15(6):e40557. doi: 10.7759/cureus.40557. PMID: 37465802; PMCID: PMC10351329.
15. Andall RG, Matusz P, du Plessis M, Ward R, Tubbs RS, Loukas M. The clinical anatomy of cystic artery variations: a review of over 9800 cases. *Surg Radiol Anat.* 2016 Jul;38(5):529-39. doi: 10.1007/s00276-015-1600-y. Epub 2015 Dec 23. PMID: 26698600.
16. Asghar A, Priya A, Patra A, Gupta P, Kumar A. Moynihan's hump of the right hepatic artery in Calot's triangle: a systematic review and meta-analysis of its incidence and surgical importance. *Surg Radiol Anat.* 2023 May;45(5):643-651. doi: 10.1007/s00276-023-03125-8. Epub 2023 Mar 17. PMID: 36932210.
17. Porzionato A, Macchi V, Stecco C, Boscolo-Berto R, Loukas M, Tubbs RS, De Caro R. Clinical Anatomy and Medical Malpractice-A Narrative Review with Methodological Implications. *Healthcare (Basel).* 2022 Sep 30;10(10):1915. doi: 10.3390/healthcare10101915. PMID: 36292362; PMCID: PMC9601975.
18. Narlapati HM, Telian SH, Peirce GS, Kaplan AJ. A Type V Aberrant Right Hepatic Duct Branching from the Cystic Duct: The Paramount Importance of Intraoperative Cholangiography in Supplementing the Critical View of Safety Technique in Laparoscopic Cholecystectomy. *CRSLS.* 2022 Mar 28;9(2):e2022.00005. doi: 10.4293/CRSLS.2022.00005. PMID: 36017506; PMCID: PMC9387367.

CONTRIBUTORS

1. **Muhammad Bilawal Khan** - Concept & Design; Drafting Manuscript
2. **Muhammad Iftikhar** - Data Analysis/Interpretation; Critical Revision
3. **Siddique Ahmad** - Concept & Design; Critical Revision



LICENSE: JGMDS publishes its articles under a Creative Commons Attribution Non-Commercial Share-Alike license (CC-BY-NC-SA 4.0).

COPYRIGHTS: Authors retain the rights without any restrictions to freely download, print, share and disseminate the article for any lawful purpose.

If includes scholarly networks such as Research Gate, Google Scholar, LinkedIn, Academia.edu, Twitter, and other academic or professional networking sites.