

## ULTRASOUND ANALYSIS OF PATIENTS WITH MASTALGIA WITH AND WITHOUT PALPABLE MASS

Humaira Anjum<sup>1</sup>, Samia Iftikhar<sup>2</sup>, Muhammad Khadim<sup>3</sup>

### How to cite this article

Anjum H, Iftikhar S, Khadim M.  
Ultrasound Analysis of Patients with  
Mastalgia with and without Palpable  
Mass. J Gandhara Med Dent Sci.  
2024;11(1):39-41

**Date of Submission:** 18-06-2023

**Date Revised:** 07-11-2023

**Date Acceptance:** 11-11-2023

<sup>1</sup>Assistant Professor, Department of  
Radiology, Khyber Teaching Hospital,  
Peshawar

<sup>3</sup>Trainee Medical Officer, Department of  
Radiology, Khyber Teaching Hospital,  
Peshawar

### Correspondence

<sup>2</sup>Samia Iftikhar, Specialist Registrar,  
Department of Radiology, Hayatabad  
Medical Complex, Peshawar

☎: +92-333-9459513

✉: [samiaiftikhar.123@gmail.com](mailto:samiaiftikhar.123@gmail.com)

<https://doi.org/10.37762/jgm.11-1.510>

### ABSTRACT

#### OBJECTIVES

To assess the clinical significance of mastalgia by investigating its association with breast lumps and the utility of diagnostic workup in cases where a palpable abnormality does not accompany mastalgia.

#### METHODOLOGY

This prospective cross-sectional study was conducted from May to July 2023 at the Radiology Department, Khyber Teaching Hospital, Peshawar. The sample size was 246, taking 80% prevalence of mastalgia, 5% margin of error and 95% confidence level. All females referred, after physical examination, to ultrasound breast with complaints of mastalgia were included in this study.

#### RESULTS

Among 246 women with a mean age of 30.9 years presented with mastalgia, 17.5% (43) had breast lump. 69.2% (170) women had BIRADS 1, while 31% (76) had BIRADS 2. None had BIRADS 3,4 or 5. 37 (15.1%) had cyclic, while 209 (85%) presented with non-cyclic mastalgia. Pathologies detected in women with lumps were abscess in 15 (34.8%), fibroadenoma in 14 (32.5%), mammary duct ectasia in 9 (20.9%), fibrocystic change in 4 (9.3%) and hematoma in 1 (2.3%) patient. Among 203 patients without palpable lump, 33 (16.3%) had positive sonographic findings, with mammary duct ectasia in 30 (91%), intramammary lymph nodes in 2 (6.1%) and fibroadenoma in 1 (3%) patient.

#### CONCLUSION

Sonographic findings of females with mastalgia were either normal or suggestive of benign lesions; hence, excessive use of ultrasound examinations may not be needed due to the fear of breast cancer.

**KEYWORDS:** Mastalgia, Ultrasound Breast, Palpable Mass, Birads

## INTRODUCTION

Mastalgia is a prevalent symptom that often leads women to seek medical attention at outpatient clinics.<sup>1,2</sup> Approximately 50% to 80% of women are believed to have encountered mastalgia at least once during their lifetime.<sup>3,4,5,6,7,8</sup> While research indicates that there is no significant association between breast pain and breast cancer, the discomfort and anxiety experienced due to pain can create lasting concerns about the possibility of breast cancer.<sup>1,9</sup> The prevalence of cancer among patients experiencing breast pain has been documented to range from 0% to 3.2% in various studies, with one particular study reporting rates as high as 7%.<sup>10,11,12,13</sup> Mastalgia has two types: cyclical and non-cyclical.<sup>1,9,14</sup> Mastalgia associated with cancer is localized, affecting less than one quadrant of the breast and persists over time. Imaging is not needed for screening purposes for cyclical, diffuse, clinically insignificant breast pain.<sup>11</sup> Breast cancer diagnoses have not increased despite the rise in referrals for

imaging due to a lack of association between mastalgia and breast cancer, according to textbooks. When women experience mastalgia, clinicians commonly request breast imaging as part of their assessment. Nevertheless, the origin of mastalgia has been associated with the breast parenchyma reaction to regular physiological hormones. Consequently, conducting breast imaging is unlikely to reveal the underlying source of pain.<sup>15</sup> In this study, we evaluated whether patients with mastalgia with or without palpable mass on clinical examination have any sonographically determined pathology to reduce the unnecessary patient referral to ultrasound, enhancing the work quality.

## METHODOLOGY

This cross-sectional, descriptive study was conducted in Khyber Teaching Hospital, OPD breast ultrasound from 2nd May to 1st July 2023. The sample size was 246, taking 80%, prevalence of mastalgia, 5 % margin of

error and 95% confidence level via consecutive, non-probability technique.<sup>6</sup> This study was conducted after ethical committee approval and informed consent from patients. Ultrasound examinations of all female patients presented with mastalgia were performed. Patients who had a history of benign or malignant breast pathology were pregnant and lactating, or presented with nipple or skin changes were excluded from this study. The machine used was a Xario 100 Toshiba, 7-10Hz probe, performed by a single consultant radiologist. SPSS version 22 was used to perform statistical analysis of the data. The mean age of patients was determined, and frequencies/percentages were calculated for ultrasound findings. The study population was stratified into four age groups, i.e., 15-25 years, 26-35 years, 36-45 years, and 46-55 years. The post-stratification chi-square test was applied, and the p-value <0.01 was taken as significant.

## RESULTS

Among 246 women with a mean age of 30.9 years (range 15-56 years) presented with mastalgia, 17.5% (43) women had breast lumps. Majority 69.2% (170) women had BIRADS 1 while 31% (76) had BIRADS 2. None had suspected malignancy, as shown in Table 01. 37 (15.1%) had cyclic, while 209 (85%) presented with non-cyclic mastalgia. The pathologies detected in women with lumps were abscess, fibroadenoma, mammary duct ectasia, fibrocystic change and hematoma (Figure 01). Among 203 patients without a palpable lump on examination, only 33 patients (16.3%) had positive findings on ultrasound, namely mammary duct ectasia, intramammary lymph nodes and fibroadenoma (Figure 02).

Table 1: BIRAD Scoring of Patients with Mastalgia

S.No	BIRAD Scoring on Ultrasound	Total number of Patients(%)
1	BIRAD 1	170 (69)
2	BIRAD 2	76 (31)
3	BIRAD 3	00
4	BIRAD 4	00
5	BIRAD 5	00

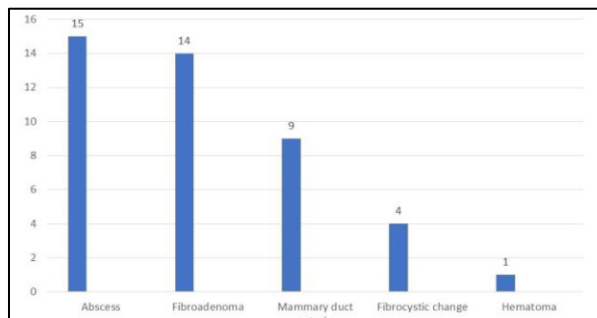


Figure 1: Ultrasound Findings in Patients with Clinically Palpable Lump n=43

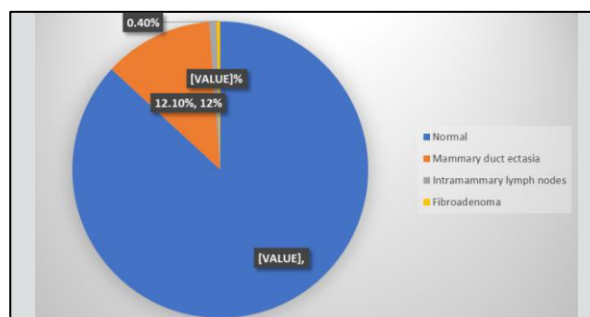


Figure 2: Ultrasound Findings in Patients without a Clinically Palpable Lump. n=203

## DISCUSSION

Mastalgia is a prevalent symptom that often leads women to seek medical attention at outpatient clinics. While research indicates that there is no significant association between breast pain and breast cancer, the discomfort and anxiety experienced due to pain can create lasting concerns about the possibility of breast cancer.<sup>1,9</sup> In our study, 246 women with a mean age of 30.9 years (range 15-56 years) presented with mastalgia, among which 37 (15.1%) had cyclic mastalgia while 209 (85%) women presented with non-cyclic mastalgia, which is comparable with a study by Aziz S et al., that found that non-cyclic mastalgia was more prevalent.<sup>16</sup> Similarly, another study reported non-cyclical mastalgia in 70.1% of patients.<sup>8</sup> In our study, women presented with mastalgia with and without palpable mass had either BI-RADS 1 or BI-RADS 2 lesions and no carcinoma was found. Our findings are in concordance with a previous study by Achom R et al. that found no cancer patients with breast pain without clinically palpable lumps.<sup>17</sup> Our study findings supported the conclusions of E. Tahir et al., which also reported normal ultrasound results in a significant majority of cases. Altintas Yasemin et al. reported similar results in mastalgia and breast cancer incidence (0.8%).<sup>4,10</sup> Similarly, our findings agreed with prior study results that found no cancer in women under 40 with diffuse mastalgia. Among women aged 30-39 with focal mastalgia, the cancer rate was 0.85%.<sup>9</sup> However, on the contrary, a study by Bajpai et al has shown a much higher incidence of malignancy (3.6%).<sup>18</sup> In our research, pathologies detected in women presenting with lumps were abscess in 15 patients (34.8%), fibroadenoma in 14 patients (32.5%), mammary duct ectasia in 9 women (20.9%) and fibrocystic change in 4 women (9.3%) and hematoma in 1 (2.3%) patient. Among 203 patients without a palpable lump on examination, only 33 patients (16.3%) had positive findings on ultrasound, with mammary duct ectasia in 30 (91%) patients, 2 (6.1%) patients had intramammary lymph nodes, and 1 (3%) patient had fibroadenoma.

The reason is that fibroadenoma was a small sub-centimetre and not palpable in fibro glandular breast parenchyma. Our study is in concordance with the results of previous studies that found that duct ectasia was the most common benign finding in women with mastalgia.<sup>2,14</sup> Our research indicated that ultrasound imaging of the breast in patients experiencing mastalgia and presenting with non-palpable abnormalities yielded results within the range of normal or benign lesions. These findings suggest that extensive ultrasound examinations may be unnecessary, thus excluding the need for excessive ultrasound examination, reducing excessive use of healthcare services, and that might not have effectively alleviated patient concerns regarding the absence or presence of malignancy. Our research outcomes corroborate the conclusions drawn by Anne C. Kushwaha et al. that the use of medical imaging for the assessment of breast pain is only associated with excessive use of healthcare resources.<sup>19</sup>

## LIMITATIONS

This study has a few rules that warrant further consideration: small sample size, single-centre setting, and need for longer follow-up.

## CONCLUSIONS

Sonographic findings of females with mastalgia were either normal or suggestive of benign lesions; hence, excessive use of ultrasound examinations may not be needed due to the fear of breast cancer. Reassurance should be provided that mastalgia is typically not indicative of breast cancer.

**CONFLICT OF INTEREST:** None

**FUNDING SOURCES:** None

## REFERENCES

- Masroor I, Afzal S, Sakhawat S, Khan N, Beg MA, Kawal D. Negative predictive value of mammography and sonography in mastalgia with negative physical findings. *J Pak Med Assoc.* 2009 Sep;59(9):598-601.
- Alsalamy J, Alaa S Alattab. Role of breast ultrasound in assessment of women with breast pain Zena. Zena. M. Al Hindawi, Hussain. *Iraq Med J.* 2018;2(3):83-5.
- Shaukat N, Jaleel F. Ultrasound findings in patients with mastalgia. *J Surg, (Pakistan).* 2016;21(4):130-3.
- Tahir E, Jabeen S, Altaf O et al. Frequency of Breast ultrasound

- Findings in patients presenting with mastalgia. *Pak J Med Health Sci.* 2023 Jun;17(6).
- athore P, Rastogi R, Pratap V, Soni S. Comparative role of x-ray mammography and sonography with sonoelastography in palpable breast lesions. *Ann Int Med Dent Res.* 2018;4(3):10.
- Taydas O, Koç U. evaluation of the relationship between breast duct diameter measured by ultrasonography and mastalgia in postmenopausal patients. *EJMI.* 2020;4(2):195-8.
- Chaudhary S, Abid Ali TaibaZ. Frequency of ultrasound findings in patients with mastalgia and its association with age in Gujranwala District. *Med Sci J Adv Res.* 2023;4(1):1-8.
- Mohammed AA. Evaluation of mastalgia in patients presented to the breast clinic in Duhok city, Iraq: cross sectional study. *Ann Med Surg (Lond).* 2020;52:31-5.
- Hot S, Coskun ZU, Ertürk A, Bender Ö, Yüzer Ö, Özay Nayır P et al. Ultrasonographic findings and breast cancer risk in women with mastalgia under 40 years. *IKSST.* 2019.
- Yasemin A, Mehmet B. Assessment of breast cancer incidence in patients with mastalgia and routine screening. *Int J Surg Res Pract.* 2019;6:094.
- Expert Panel on Breast Imaging, Holbrook AI, Moy L, Akin EA, Baron P, Didwania AD et al. ACR appropriateness criteria® breast pain. *J Am Coll Radiol.* 2018 Nov 1;15(11S):S276-82.
- Holbrook AI, Zhang J, D'amico K, Liu Y, Newell MS. The association of breast pain with malignancy. *Journal of Breast Imaging.* 2019 Sep;1(3):177-81.
- Mema E, Cho E, Ryu YK, Jadeja P, Wynn R, Taback B et al. In the setting of negative mammogram, is additional breast ultrasound necessary for evaluation of breast pain? *Curr Probl Diagn Radiol.* 2019 Mar-Apr;48(2):117-20.
- Li P, Simpson A, Dietz J. Work-up and management of breast pain. *Ann Breast Surg.* 2021;5:27.
- Komenaka IK, Nodora J, Martinez ME, Hsu C-H, Wong T, Shah A, et al. Mastalgia is not an indication for mammogram. *J Am Board Fam Med.* 2022;35:998-1006.
- Aziz S, Sattar A, Walid A, Rahim A, Naz N, Ara H. Sonographic ultrasound evaluation of mastalgia and to determine the relationship between breast duct diameter and severity of mastalgia. *J Liaq Uni Med Health Sci.* 2023 Jun 21;22(2):110-4.
- Rahaman HA, Chinnikatti SK. Clinical and USG findings of patients presented with breast pain. *Med Res Chronicles.* 2021 Jun 2;8(3):195-9.
- Bajpai A, Santra Db, Sarkar S, Sinha D. Relevance of ultrasound in mastalgia: experience at a peripheral hospital. *Int J Sci Res.* 2018;7(11).
- Kushwaha AC, Shin K, Kalambo M, Legha R, Gerlach KE, Kapoor MM et al. Overutilization of health care resources for breast pain. *AJR Am J Roentgenol.* 2018 Jul;211(1):217-23.

## CONTRIBUTORS

- Humaira Anjum** - Concept & Design; Critical Revision; Supervision; Final Approval
- Samia Ifkhar** - Data Analysis/Interpretation; Drafting Manuscript
- Muhammad Khadim** - Data Acquisition; Data Analysis/Interpretation



LICENSE: JGMDS publishes its articles under a Creative Commons Attribution Non-Commercial Share-Alike license (CC-BY-NC-SA 4.0).  
 COPYRIGHTS: Authors retain the rights without any restrictions to freely download, print, share and disseminate the article for any lawful purpose.  
 It includes scholarly networks such as Research Gate, Google Scholar, LinkedIn, Academia.edu, Twitter, and other academic or professional networking sites.