

## TO CORRELATE THE EXPRESSION OF KRAS AND BRAF V600E WITH HISTOLOGICAL GRADES AND VARIANTS IN TISSUE SAMPLES OF COLORECTAL CARCINOMA

Hina Wasti<sup>1</sup>, Sumayyah Shawana<sup>2</sup>, Sehrish Shafique<sup>3</sup>, Yumna Shahid<sup>4</sup>, Kiran Saleem<sup>5</sup>, Santosh Kumar Sidhwani<sup>6</sup>

### Correspondence

<sup>1</sup>Hina Wasti, Assistant Professor, Histopathology, Bahria University Health Sciences, Karachi

☎: +92-334-3113237

✉: [drhinafaisal@gmail.com](mailto:drhinafaisal@gmail.com)

<sup>2</sup>Senior Professor, Histopathology, Bahria University Health Sciences, Karachi

<sup>3</sup>Associate Professor, Department of Medicine, Bahria University Health Sciences, Karachi

<sup>4</sup>Senior Lecturer, Department of Anesthesia, Taj Complex, Karachi

<sup>5</sup>Lecturer, Department of Pathology, Bahria University Health Sciences, Karachi

<sup>6</sup>Associate Professor, Department of Pathology, Ziauddin Medical College, Karachi

### How to cite this article

Wasti H, Shawana S, Shafique S, Shahid Y, Saleem K, Sidhwani SK. To Correlate The Expression of Kras And Braf V600e With Histological Grades and Variants in Tissue Samples of Colorectal Carcinoma. J Gandhara Med Dent Sci. 2023;10(2): 52-56 <https://doi.org/10.37762/jgm.10-2.399>

### INTRODUCTION

Colorectal cancer (CRC) has been identified as the most common cancer of the digestive tract. The third most prevalent cancer in both male and female genders over 50 years of age represents almost 10% of all registered malignant diseases.<sup>1,2</sup> About one million cases of colorectal cancer are diagnosed annually in the world.<sup>3</sup> In Pakistan, CRC accounts for 52% of all gastrointestinal tumors.<sup>4</sup> Several genetic and epigenetic mutations have been identified in various proto-oncogenes and tumor suppressor genes which involve distinct pathways, including chromosomal instability (CIN), microsatellite instability (MSI), and CpG island methylation phenotype (CIMP).<sup>5</sup> KRAS and BRAF being the prime oncogenic factors for colorectal cancer play a significant role in its pathogenesis. BRAF

belongs to the RAF family of proteins, encoding a 766 amino acid serine/threonine kinase. BRAF belongs to the RAF family of proteins, and its gene is located on chromosome 7, encoding a 766 amino acid serine/threonine kinase. The vast majority of mutated BRAF is V600E resulting from a point mutation having 80% cancerous potential of the RAS-RAF-MAPK pathway. BRAFV600E significantly increases the DNA methylation of CIMP-associated markers in primary colorectal tumors.<sup>6</sup> BRAF V600E mutations are assumed to be an early event in the serrated pathway of tumorigenesis. BRAF V600E mutations in colorectal carcinoma have been observed to be associated with proximal location, advanced TNM stage, T-lymphocyte infiltration and mucinous histology.<sup>7</sup> The evaluation of BRAF V600E by immunohistochemistry (IHC) is a simple, rapid and

### ABSTRACT

#### OBJECTIVES

*This study aimed to correlate the expression of KRAS and BRAF V600E with histological grades and variants in tissue samples of colorectal carcinoma.*

#### METHODOLOGY

*In this cross-sectional study total of 51 cases of Colorectal cancer (CRC) were analyzed for immunohistochemical staining using KRAS and BRAF antibodies on representative tissue blocks. Clinical and pathological records were retrieved for the collection of data. The results of the immunohistochemical analysis were correlated with the recorded clinicopathological parameters.*

#### RESULTS

*Fifty-one cases of CRC were analyzed for immunoexpression of KRAS and BRAF V600E. The age of the patients ranged from 14 to 85 years, with a mean age of 60.96 years. Among the 51 cases, 37(72.5%) cases were males and 14(27.4%) were females. 37(72.5%) were localized to left side colon and 14(27.4%) were found in the right colon. For KRAS immunostaining, 41(80.3%) out of 51 cases showed overexpression, while the remaining 10(19.6%) cases revealed negative expression. In the case of BRAF V600E, positive expression was seen in 20(39.2%) cases, whereas 31(60.7%) cases showed negative expression of BRAFV600E. A significant association was seen between KRAS overexpression and histological variants, i.e. glandular carcinomas.*

#### CONCLUSION

*Over-expression of KRAS was observed in advanced tumors. The presence of BRAF V600E mutation in the present study signifies the importance of BRAF V600E inhibitors as a potential alternate therapeutic tool in EGFR inhibitors and chemotherapy-resistant tumors.*

**KEYWORDS:** Colorectal cancer, KRAS & BRAF V600E Immunohistochemistry, Tumor Grades, Histological Variant.

inexpensive method for detecting the presence of mutated protein.<sup>8</sup> A study concluded that early screening of BRAF V600E might improve the evaluation of the risks for colorectal cancer, help in effective management of the patients, and also aid in predicting the prognosis of CRCs. Evaluation of BRAF V600E along with RAS mutation was considered valuable when considering target therapy for metastatic colorectal carcinoma.<sup>9</sup> Mutations of the RAS family have been identified as the most common phenomenon in almost all human malignancies, including colorectal cancer. The most frequently occurring gene of the RAS family is KRAS (Kirstein Ras), a membrane-bound protein of the receptor tyrosine kinase pathway. It possesses important guanosine triphosphate/ guanosine diphosphate (GTP/GDP) binding properties, activating KRAS and stimulating MAPK and PI3K/AKT signalling pathways, thereby causing rapid cell growth. The detection of KRAS expression can be done by routine immunohistochemistry in histopathological laboratories.<sup>10</sup> Limited data is available regarding the expression of KRAS and BRAF in colorectal carcinoma in the Pakistani population. This study hence aims to evaluate the expression of these markers in our population and to correlate it with histological grades to aid the selection of effective treatment options.

## METHODOLOGY

This cross-sectional study was based on the analysis of colonic biopsies received in the Department of Pathology, Pakistan Navy Ship Shifa hospital Karachi. Ethical approval was obtained from the Ethical Review Committee of Bahria University Medical and Dental College before commencing the study. The samples were collected, including biopsies and colectomy specimens. The sample size was calculated using software G- POWER (version 3.1.9.2), taking a 95% confidence interval and a 5% margin of error. The required sample size was found to be 51. All colonic surgical specimens diagnosed as primary colorectal carcinoma obtained before therapy and patients willing to participate in the study were included. In contrast, poorly fixed tissue, inadequate material, metastatic tumors, post-radiotherapy specimens, and patients who refused to participate in the study were excluded from this research. From March 2016 to March 2019, 291 colorectal samples were received at our setup during the study period. Both biopsies (n=29) and colectomy specimens (n=22) were analyzed for histopathological diagnosis. Among them, 240 cases were reported as benign lesions, while 51 cases were diagnosed as colorectal cancer. Hematoxylin, eosin, anti-BRAF V600E and anti-KRAS immunohistochemical staining

were performed on the formalin-fixed paraffin-embedded tissues. The clinicopathological data, including age, sex, location, microscopic types, and histological grade, were collected for statistical analysis, for immunohistochemistry sections of 3 to 5µm thickness were taken from FFPE tumor blocks picked on poly-L-lysine coated slides. Antigen retrieval was done using retrieval solution (pH 6.0 citrate buffer 10 x) in the water bath at 98-99 ° C for 40 minutes. Endogenous peroxidase was blocked using a hydrogen peroxide-blocking solution. BRAF V600E dilution was done in the ratio of 1:20 as per company-provided protocol. Primary antibodies were applied to cover the section. Sections were incubated for 30 min with labelled secondary antibodies. DAB substrate chromogen solution (1 ml substrate buffer + 1 drop DAB chromogen) was applied to the cover section, incubated for 2 minutes, washed and counterstained with hematoxylin, dehydrated with ethanol, cleared in xylene and mounted. The slides were then visualized under a light microscope. Tissue samples to which no primary antibody had been added were used as negative controls. Immunoreactivity was scored taking into account the percentage of stained tumor cells (Yellow-brown color) and staining intensity. For KRAS, membranous staining was scored as 3(+) when the majority of cells (>75%) showed positive staining, 2(+) when 50–75% and 1(+) when 25-50% of cells were stained. The staining was taken as negative when <25% of cells revealed staining with KRAS protein. Scores 3(+), 2(+) and 1(+) were considered an expression of KRAS protein. The intensity of KRAS staining was graded as strong (3+), moderate (2+), weak (1+) and no staining (0). Human Placental tissue was used as a positive control. For BRAF V600E, the intensity of cytoplasmic tumor cell staining was scored as weak (1), moderate (2) and strong (3). The cytoplasmic staining of BRAF V600E of at least medium intensity in more than 10% of tumor cells was considered positive, while the tumors were considered immune negative when there were <10% of stained tumor cells. Papillary thyroid carcinoma with a documented BRAF V600E mutation was used as a positive control. Statistical analysis was done using SPSS version 23.0. Continuous variables were presented as mean and standard deviation. Categorical variables were presented as frequency and percentage. Chi-square and Fisher's exact test was used to assess the association between KRAS & BRAF expression with histological grades. P≤0.05 was considered statistically significant.

## RESULT

In this study, 51 cases of CRC were analyzed for immunoexpression of KRAS and BRAF V600E. The

age of the patients ranged from 14 to 85 years, with a mean age of 60.96 years. Among the 51 cases, 37(72.5%) cases were males and 14(27.4%) were

females. 37(72.5%) were localized to left side colon and 14(27.4%) were found in the right colon.

**Table 1: Intensity and extent of KRAS-Immunoreactivity in Diagnosed Cases of Colorectal Carcinoma (n=51)**

Extent				Intensity				Total	
0	01	02	03	0	01	02	03		
02 (25%)	03 (37.5%)	01 (12.5%)	02 (25%)	0 (0%)	08 (100%)	0 (0%)	0 (0%)	08	
01 (5%)	05 (25%)	03 (15%)	11 (55%)	0 (0%)	0 (0%)	20 (100%)	0 (0%)	20	
01 (4.3%)	01 (4.3%)	03 (13.04%)	18 (78.2%)	0 (0%)	0 (0%)	0 (0%)	23 (100%)	23	

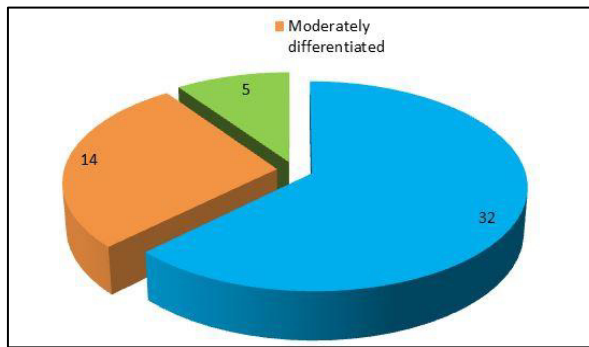
Extent of reactivity: 0, < 25%; 1+, 25-50%; 2+, 50-75%; 3+, >75% Intensity of reactivity: 0 = no staining; 1+ = weak staining; 2+ = moderate staining, 3+ = strong staining.

**Table 2: Expression of BRAF-V600E in Colorectal Carcinoma (n=51)**

BRAF-V600E Expression	No Cases of Colorectal Carcinoma	%age
Positive Expression	20	39.2 %
Negative Expression	31	60.8%

**Positive Expression:** cytoplasmic staining of at least medium intensity in more than 10% of tumor cells

**Negative Expression:** tumors were considered immune negative when there was <10% of stained tumor cells.



**Figure 1: Distribution of Colorectal Carcinomas according to a Grade of Differentiation**

**Table 3: Association of Tumor Grades and Histological Variants with KRAS Overexpression (n=51)**

Tumor Grades & Histological Variants	Total Numbers	KRAS Overexpression		P-Value
		Positive	Negative	
Glandular Adenocarcinoma	32(62.7%)	29	03	0.003
Mucinous Carcinoma/SR	16(31.4%)	12	04	
Poorly Cohesive	02(3.9%)	0	02	
Ciribriiform Pattern	01(2.0%)	0	01	

**Table 4: Association of Tumor Grades and Histological Variants -with BRAF V600E expression (n=51)**

Tumor Grades & Histological Variants	Total Numbers	BRAF V600E		P-Value
		Positive	Negative	
Glandular Adenocarcinoma	32(62.7%)	14	18	0.862
Mucinous Carcinoma/SR	16(31.4%)	05	11	
Poorly Cohesive	02(3.9%)	01	01	
Ciribriiform Pattern	01(2.0%)	0	01	

**DISCUSSION**

This study has been done to determine the frequency of colorectal cancers received at our setup and to evaluate the expression of KRAS and BRAF V600E in these cases for selecting effective treatment options. In the present study, out of 51 cases, 41(80.39%) cases of colorectal cancer showed overexpression for KRAS protein. According to the study by Elsabah and Adel, 26 metastatic colorectal cancer cases were included, out of which 11 (42.3%) were found to be positive for KRAS immunostaining. 7 (26.9%) cases in this study showed strong positivity, and 4 (15.4%) cases were moderately positive.<sup>10</sup> The present study's findings are also in coherence with a study conducted by Zlatian et al Various studies showed overexpression of KRAS, BRAF, MEK, and ERK both by IHC and q PCR and suggested that IHC be an equally effective diagnostic technique.<sup>11,12,13,14</sup> As the present study has utilized immunohistochemistry to evaluate the expression of KRAS protein in colorectal cancer. We can use our results as a foundation for further research evaluation of KRAS expression. In the current study, we observed the association of KRAS overexpression with histological grades, tumor grades, and histological variants. Our results revealed a significant correlation with histological variants with KRAS overexpression with (p value=0.003). Other studies have also shown a significant association between KRAS expression and histological variants.<sup>15,16</sup> With respect to BRAF V600E immune expression, out of 51cases, 20(39.2%) cases showed positive BRAF V600E expression, while

remaining 31(60.8%) cases revealed no expression of BRAFV600E on IHC. These results are in agreement with other studies which concluded positive BRAF V600E expression on IHC, as well as on genetic analysis.<sup>17,18,19</sup> In this study, we did not find a significant correlation between the positive expression of BRAF V600E with tumor grades and histological variants. These results are under investigation, which did not find any significant correlation between these parameters and BRAF V600E expression.<sup>20</sup> In the present study, no significant correlation was seen between the expression of KRAS and BRAFV600E. Both KRAS and BRAF act as independent markers. A study found that tumor stage is important for evaluating BRAF mutant tumors for treatment options. Early tumor stage may be prone to BRAF-specific inhibition alone. As tumor stage advances, various processes must be aimed owing to the concentration of mutations. It has been suggested that RAF inhibitor combination strategies can suppress feedback reactivation of the MAPK signalling pathway and improve efficacy in BRAF-mutant colorectal cancers.<sup>21</sup> As has been established, KRAS expression is usually seen in rapidly dividing cells in aggressive tumors. KRAS expression in the present study is also associated with advanced tumors. Other BRAF V600E expression was also noted in the normal mucosa adjacent to the tumor, signifying BRAF mutation as a potential early change in tumorigenesis of these cancers. Also, the presence of BRAF V600E mutation in the current study stresses the need for using anti-BRAF V600E as a routine biomarker by IHC in colorectal carcinoma diagnosis. It emphasizes the significance and importance of BRAF V600E inhibitors as a potential alternate therapeutic tool in EGFR inhibitors and chemotherapy-resistant tumors.

### LIMITATIONS

The main limitations of this study are that the sample size is small, and a larger sample size can provide further avenues for determining histopathological correlation.

### CONCLUSION

KRAS expression in colorectal carcinomas is usually seen in rapidly dividing cells in aggressive tumors, and in the present study, overexpression of KRAS was observed in advanced tumors. BRAF V600E expression in normal mucosa adjacent to the tumor stresses the importance of BRAF V600E immunohistochemistry as a diagnostic tool for early detection of the lesion. Our study's significant association of KRAS expression with tumor grades and

histological variants illuminates the diagnostic and prognostic attributes of KRAS and BRAF V600E immunohistochemistry in routine clinical labs. As the surrounding normal mucosa was also considered while assessing the results of IHC, the study can give an idea regarding the expression of abnormal protein in early lesions. Immunohistochemistry for BRAF V600E was done against the protein product of a mutated version of the oncogene and showed strong expression in almost 40% of cases. This is a significant finding and provides a platform for further studies, especially those concerned with early detection. This significance can be employed for assessing the prognosis and determining the need for adjuvant chemotherapy in the patients. The molecular analysis would be required to strengthen the results in future.

**CONFLICT OF INTEREST:** None

**FUNDING SOURCES:** None

### REFERENCES

1. Li-Chang HH, Kirsch R, Conner J, Sari A, Pollett A, El-Zimaity H, Jain D, Celli R, Reid SL, Riddell RH, Pollett A. Colorectal Carcinoma. Atlas of Intestinal Pathology: Volume 1: Neoplastic Diseases of the Intestines. 2019:15-25.
2. Zdravkovic N, Pavlovic M, Radosavljevic G, Jovanovic I, Arsenijevic A, Zdravkovic N, Maric V, Loncarevic S, Srzentic Z, Jovanovic I. Serum levels of immunosuppressive cytokines and tumor markers in metastatic colorectal carcinoma. Journal of BUON. 2017;22:1-8.
3. Liu SL, Cheung WY. Role of surveillance imaging and endoscopy in colorectal cancer follow-up: Quality over quantity?. World journal of gastroenterology. 2019 Jan 7;25(1):59.
4. Hohenberger W. Colorectal cancer—heading to the future. Innovative Surgical Sciences. 2018 Mar 1;3(1):1-2.
5. Nikolouzakis TK, Vassilopoulou L, Fragkiadaki P, Mariolis Sapsakos T, Papadakis GZ, Spandidos DA, Tsatsakis AM, Tsioussis J. Improving diagnosis, prognosis and prediction by using biomarkers in CRC patients. Oncology reports. 2018 Jun 1;39(6):2455-72.
6. Haley L, Tseng LH, Zheng G, Dudley J, Anderson DA, Azad NS, Gocke CD, Eshleman JR, Lin MT. Performance characteristics of next-generation sequencing in clinical mutation detection of colorectal cancers. Modern Pathology. 2015 Oct;28(10):1390-9.
7. Loupakis F, Moretto R, Aprile G, Muntoni M, Cremolini C, Iacono D, Casagrande M, Ferrari L, Salvatore L, Schirripa M, Rossini D. Clinico-pathological nomogram for predicting BRAF mutational status of metastatic colorectal cancer. British journal of cancer. 2016 Jan;114(1):30-6.
8. Roma C, Rachiglio AM, Pasquale R, Fenizia F, Iannaccone A, Tatangelo F, Antinolfi G, Parrella P, Graziano P, Sabatino L, Colantuoni V. BRAF V600E mutation in metastatic colorectal cancer: methods of detection and correlation with clinical and pathologic features. Cancer biology & therapy. 2016 Aug 2;17(8):840-8.
9. Tan C, Du X. KRAS mutation testing in metastatic colorectal cancer. World journal of gastroenterology: WJG. 2022 Oct 7;18(37):5171.
10. Jasar D, Filipovski V, Kubelka-Sabit K. Clinicopathological



- and histomorphological association in K-ras mutated colorectal cancer. *Virchows Archiv*. 2022(481):1-364.
11. Zlatian OM, Comănescu MV, Roșu AF, Roșu LU, Cruce M, Găman AE, Călina CD, Sfredel V. Histochemical and immunohistochemical evidence of tumor heterogeneity in colorectal cancer. *Rom J Morphol Embryol*. 2015 Jan 1;56(1):175-81.
  12. Wan XB, Wang AQ, Cao J, Dong ZC, Li N, Yang S, Sun MM, Li Z, Luo SX. Relationships among KRAS mutation status, expression of RAS pathway signaling molecules, and clinicopathological features and prognosis of patients with colorectal cancer. *World journal of gastroenterology*. 2019 Feb 21;25(7):808
  13. Kim JK, Seong CY, Bae IE, Yi JW, Yu HW, Kim SJ, Won JK, Chai YJ, Choi JY, Lee KE. Comparison of immunohistochemistry and direct sequencing methods for identification of the BRAF V600E mutation in papillary thyroid carcinoma. *Annals of surgical oncology*. 2018 Jun 1;25(6):1775-81.
  14. Xie MZ, Li JL, Cai ZM, Li KZ, Hu BL. Impact of primary colorectal Cancer location on the KRAS status and its prognostic value. *BMC gastroenterology*. 2019 Dec;19(1):46.
  15. Bisht S, Ahmad F, Sawaimoon S, Bhatia S, Das BR. Molecular spectrum of KRAS, BRAF, and PIK3CA gene mutation: determination of frequency, distribution pattern in Indian colorectal carcinoma. *Medical oncology*. 2014 Sep 1;31(9):124.
  16. Hussain M, Waqas O, Hassan U, Loya A, Akhtar N, Mushtaq S, Yusuf MA, Syed AA. Right-sided and left-sided colon cancers are two distinct disease entities: an analysis of 200 cases in Pakistan. *Asian Pac J Cancer Prev*. 2016;17(5):2545-8.
  17. Lemos Garcia J, Rosa I, Saraiva S, Marques I, Fonseca R, Lage P, Francisco I, Silva P, Filipe B, Albuquerque C, Claro I. Routine Immunohistochemical Analysis of Mismatch Repair Proteins in Colorectal Cancer—A Prospective Analysis. *Cancers*. 2022 Jul 31;14(15):3730.
  18. Dvorak K, Higgins A, Palting J, Cohen M, Brunhoeber P. Immunohistochemistry with Anti-BRAF V600E (VE1) mouse monoclonal antibody is a sensitive method for detection of the BRAF V600E mutation in colon cancer: Evaluation of 120 cases with and without KRAS mutation and literature review. *Pathology & Oncology Research*. 2019 Jan 15;25(1):349-59.
  19. González-Colunga KJ, Lino-Silva LS, Salcedo-Hernández RA, Ruiz-García EB, Zepeda-Najar C. BRAF V600E Expression by Immunohistochemistry in Colon Cancer and Clinico-pathologic Features Associated with BRAF-Mutated Colonic Cancers in Mexican Patients. *Journal of gastrointestinal cancer*. 2019 Jan 8:1-6.
  20. Chen D, Huang JF, Liu K, Zhang LQ, Yang Z, Chuai ZR, Wang YX, Shi DC, Huang Q, Fu WL. BRAFV600E mutation and its association with clinicopathological features of colorectal cancer: a systematic review and meta-analysis. *PLoS one*. 2014;9(3).
  21. Cao J, Zhu X, Sun Y, Li X, Yun C, Zhang W. The genetic duet of BRAF V600E and TERT promoter mutations predicts the poor curative effect of radioiodine therapy in papillary thyroid cancer. *European Journal of Nuclear Medicine and Molecular Imaging*. 2022 Aug;49(10):3470-81.

## CONTRIBUTORS

1. **Hina Wasti** - Concept & Design; Data Acquisition; Data Analysis/Interpretation; Drafting Manuscript; Critical Revision; Supervision; Final Approval
2. **Sumayyah Shawana** – Data Analysis Interpretation; Critical Revision; Supervision
3. **Sehrish Shafique** – Concept & Design; Data Analysis/Interpretation; Critical Revision; Final Approval
4. **Yumna Shahid** - Data Acquisition; Drafting Manuscript; Supervision
5. **Kiran Saleem** – Data Acquisition; Drafting Manuscript; Supervision
6. **Santosh Kumar Sidhwani** – Data Analysis/Interpretation; Supervision



LICENSE: JGMDS publishes its articles under a Creative Commons Attribution Non-Commercial Share-Alike license (CC-BY-NC-SA 4.0).  
 COPYRIGHTS: Authors retain the rights without any restrictions to freely download, print, share and disseminate the article for any lawful purpose.  
 It includes scholarly networks such as Research Gate, Google Scholar, LinkedIn, Academia.edu, Twitter, and other academic or professional networking sites.