

COMPARATIVE EVALUATION OF LAMINA CRIBROSA ANATOMICAL PARAMETERS WITH RETINAL NERVE FIBER LAYER THICKNESS DEFECTS IN PRIMARY OPEN-ANGLE GLAUCOMA CASES AND CONTROLS

Ayesha Saba Naz¹, Aisha Qamar², Ambreen Surti³, Sehrish Shafique⁴, Yasmeen Mahar⁵, Yawar Zaman⁶, Nasim Marvi⁷

Correspondence

¹ Ayesha Saba Naz, Associate Professor Anatomy, Department of Anatomy BUHSC, Karachi

☎: +92-345-2257226

✉: drayeshasaba@hotmail.com

² Professor, Department of Anatomy, BUHSC, Karachi

³ Assistant Professor, Department of Anatomy, BUHSC, Karachi

⁴ Associate Professor, Department of Medicine, BUHSC, Karachi

⁵ Associate Professor, Department of Anatomy, BUHSC, Karachi

⁶ Assistant Professor, Department of Ophthalmology, Eye Specialist Liaquat College of Medicine and Dentistry & Darul Sehat Hospital, Karachi

⁷ Senior Lecturer, Department of Anatomy, Jinnah Sindh Medical Institute

How to cite this article

Naz AS, Qamar A, Surti A, Shafique S, Mahar Y, Zaman Y, et al. Comparative Evaluation of Lamina Cribrosa Anatomical Parameters with Retinal Nerve Fiber Layer Thickness Defects in Primary Open-Angle Glaucoma Cases and Controls. J Gandhara Med Dent Sci. 2023; 10(1): 3-6
<https://doi.org/10.37762/jgm.10-1.369>

ABSTRACT**OBJECTIVES**

To assess the lamina cribrosa (LC) anterior lamina cribrosa depth (ALCD), lamina cribrosa thickness (LCT) and retinal nerve fiber layer thickness (RNFLT) in primary open-angle glaucoma (POAG) cases and age-matched controls and to compare these anatomical variables among POAG cases and age-matched controls.

METHODOLOGY

The case-control study was researched at Al-Ain Eye Institute, Karachi, in four month's duration (November 2018 till February 2019). Expert Eye specialist recruited 57 POAG cases and 46 age-matched healthy controls. Observation of intraocular pressure (IOP) and open angle was done using Goldmann tonometry and Slit-lamp biomicroscopy with stereoscopic ophthalmoscopy respectively. Visual field parameters of mean deviation (MD) and pattern standard deviation (PSD) measured using Humphrey Field Analyzer. Highly sensitive spectral domain ocular coherence tomography with enhanced depth imaging (EDI-OCT) was used to determine ALCD, LCT and RNFLT.

RESULTS

Statistically significant results were produced by RNFLT defects when it is compared in groups of mild with moderate cases of POAG (P-value 0.037). ALCD and LCT did display an association with RNFLT defects but did not produced statistically significant results.

CONCLUSION

Assessments of ALCD and LCT can provide important prognostic evidence about RNFLT and can assist in future planning of mild and moderate cases suffering from POAG.

KEYWORDS: LC, ALCD, LCT, RNFLT, SD-OCT, EDI-OCT

INTRODUCTION

Glaucoma is a precarious ocular condition characterized by impairment of optic nerve head that leads to glaucomatous optic nerve neuropathy (GON).¹ The outcomes of glaucoma consist of the panoply of irreversible loss of vision, of which glaucoma is one of the leading causes. A massive figure of more than 75 million people are affected globally, and POAG is the most prevalent type of glaucoma worldwide.² It is estimated that around 57.5 million people are sufferers of POAG.³ Since glaucoma remains silent for decades, it usually remains undiagnosed, hence is a dire need for exploration of measures focused towards the screening of the disease and the methods employed that can prove prophylactic against its deleterious effects.⁴ LC has recently become a keen interest of researchers worldwide, as it has proven to be closely associated with the structural damage at the optic nerve head, which results in damage to retinal nerve

fiber layer (RNFL) and visual field losses. The onset of LC morphological aberrations occurs way before the initiation of GON, hence its imaging and observation can be regarded as an early sign of glaucomatous damage.^{5,6} Exploration of anatomical parameters of LC is advantageous and promises to play a vital role in management of glaucoma. LC can be visualized by non-invasive imaging using spectral domain ocular coherence tomography (SD-OCT) with EDI.⁷ In Pakistan, LC has never been researched ever, so this study can be regarded as a primary work, which was directed towards the assessment of RNFLT along with the structural variables of ALCD and LCT in POAG cases and age-matched healthy controls.

METHODOLOGY

Al-Ain Eye Institute, Karachi was the center for this case-control study, where in four months (November 2018 till February 2019) the research sample

collection was completed after acceptance from ERC of Bahria University Medical and Dental College. Calculation of sample size of 103 (57 cases and 46 controls) done using comparing two means. Calibration of cases was established over the research conducted by, after taking their informed consent.⁸ Non-probability purposive sampling technique was employed. Inclusion criteria: The subjects selected as POAG cases had 1. Intraocular pressure (IOP) of >22mmHg calculated by Goldmann tonometry (At-900, Haag Striet, Switzerland). Open angle measured by Slit-lamp (Topcon SL-D 7, Topcon Corporation, Tokyo, Japan) and stereoscopic ophthalmoscope (WelchAllyn, USA). Had least visual acuity of >20/40. Visual field assessment carried out as external normal limits on glaucoma hemifeild test, with three nonstandard points with P <5% probability of being normal, 1 with P<1% by pattern deviation, pattern standard deviation of <5% on automated Humphry 50-2 VF analysis (Medmont M 700 Automated Perimeter, fast threshold, Vermont, Australia) for visual field analysis).⁹ Exclusion criteria: All other variants of glaucoma, moderate to severe cataract, head trauma, neurological, autoimmune defects, diabetic and hypertensive retinopathies were excluded from the study. ALCD and LCT assessed using SD-OCT with enhanced depth imaging (REVO nx/SOCT Copernicus REVO OPTOPOL Technology, Wavelength 830nm, Axial resolution 2µm, scan speed 1,10,000 scans/sec, scan time 1.37seconds, OPTOPOL Technology Sp. Z o.o, ul. Zabia 42, 42-400 Zawiercie, Poland), with standard guidelines 10. ALCD was drawn as a link between the ends of Bruch’s membrane and anterior border of LC.¹⁰ Whereas LCT was estimated by measuring the zone between the anterior and posterior borders of LC.¹⁰ The categorization of cases into mild and moderate groups was based over standardized outlines used before. VF-MD <-6 dB but >-2dB graded as mild whereas VF-MD > -6 dB but <-12 dB graded as moderate glaucoma.^{11,12} For Statistical analysis of the data, SPSS 23 version was used. Margin of error for sample size calculation was 5% with confidence interval for mean 95%. Mann-Whitney-U test for ALCD and independent sample T-test was used for analysis of LCT. Fischer exact test was employed for statistical evaluation of RNFLT defects. P-value of < 0.05 was taken as significant.

RESULTS

Out of 56 POAG cases, 7 were excluded due to Out of 56 POAG cases, 7 were excluded due to their inability to comprehend the visual field test. 49 cases had mild glaucoma. Overall majority of cases had superior RNFLT defects (Superior n=13, Superior and inferior n=10) so superior sectorial area was found out to be

more susceptible and to be thoroughly checked upon by the ophthalmologists. 19 mild cases did not have RNFLT defects. Table 1 shows Superior and Superior and inferior RNFLT defects were also prevalent in moderate glaucoma cases (Superior n=2, Superior and inferior n=5). RNFLT defects when compared between cases and controls produced statistically significant result (table 1).

Table 1: Comparison of Retinal Nerve Fiber Layer Defects With Anterior Lamina Cribrosa Depth (ALCD) And Lamina Cribrosa Thickness (LCT) In Mild And Moderate Glaucoma Primary Open-Angle Glaucoma (POAG)

Retinal Nerve Fiber Layer Defects	Mild Glaucoma (Vf-MD ≤ -6) (n=49)	Moderate Glaucoma (Vf-Md > -6 To -12) (n=8)	P-Value	
Superior	13 26.5%	02 25.0%	0.037* γ	
Inferior	04 8.2%	0 0.0%		
Not Present	19 38.8%	0 0.0%		
Superior And Inferior	10 20.4%	05 62.5%		
Superior, Inferior And Nasal	02 4.1%	0 0.0%		
Superior, Inferior, Temporal And Nasal	01 2.0%	01 12.5%		
Anterior Laminar Depth (µm)	300.13 ± 148.94	305.41 ± 130.15		0.778 §
Lamina Cribrosa Thickness (µm)	221.11 ± 80.14	199.40 ± 80.19		0.55 †

P-value of ≤0.05 is significant and shown with asterisk* γ- Fischer exact test, §- Mann Whitney-U test , †- Independent sample T- test Units used: µm-micrometer, When the mild, moderate POAG cases were compared with age-matched healthy controls, they produced a statistically significant result as shown in Figure 1.

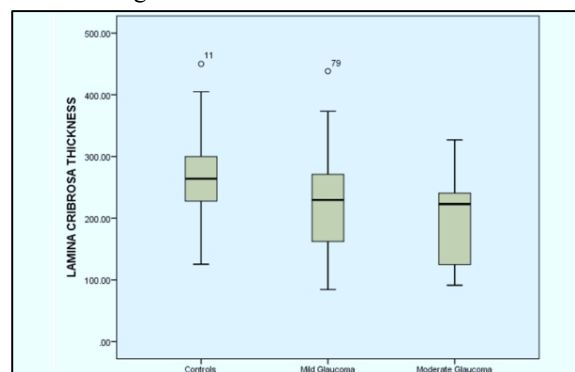


Figure 1: Box Plot Showing The Ranges of Lamina Cribrosa Thickness (LCT) In Controls, Mild And Moderate Glaucoma Subjects. The LCT Had Reflected A Statistically Significant Result.

DISCUSSION

The present research work over LC can be regarded as a principal research done for the first time ever in Pakistan; hence it can be regarded as a milestone in our settings. The study appraised and paralleled the anatomical variables of LC (ALCD and LCT) with the RNFLT defects; categorized in mild and moderate POAG cases and also in age-matched healthy controls. Noteworthy statistically significant results were elaborated in our study that can be equated with any international scholarly work conducted worldwide over LC. As seen in our study, the superior RNFLT defects were more common in the mild and moderate cases of POAG. A similar predilection for the superior retinal sectorial damage was discovered by other studies.¹³ The detection of RNFLT defects holds vital importance as the structural damage to the optic nerve head occurs way before the onset of visual field impairments.¹⁴ The RNFLT defects attained in any sector are closely linked with the functional impairment appearing as visual field losses.¹⁵ Inferior RNFLT defects were the second most appearing defects obtained in our study. Similar results had been elaborated by Tong YX in which inferior RNFLT defects had also been reported in the POAG cases.¹⁶ Worldwide it has been proven that the severity of POAG is correlated with progressive loss of retinal ganglion cells, and subsequently the overall thickness of retinal deteriorates. Similar findings can also be interrelated from our study with other research works.¹⁷ Progressive loss of RNFLT and worsening of glaucoma had also been proven by Bhat KS.¹⁸ Similar to our study superior RNFLT defects were preponderant in this study as well. When the structural parameters of LC, LCT was compared between cases of mild and moderate glaucoma and age-matched healthy controls, it produced statistically significant results as were also elaborated in other studies.¹⁹ LCT is the parameter of LC which our study authenticates to be watched for in the management of POAG.

LIMITATIONS

EDI-OCT is a highly specific but expensive instrument and very few setups have the instrument in our country. This was the constraint in conducting this study at a single center.

CONCLUSION

A deeper LCT and superior, superior-inferior RNFLT defects signify the greater severity of POAG and these are the non-invasive anatomical ocular parameters that can aid ophthalmologists to monitor the progression and prognosis of the disease. LC is the latest boom in

the research world. In Pakistan this is the pioneer study over LC carried out ever. More aspects of LC can be studied as LC is a promising factor which can prove prophylactic in the management of POAG and other forms of glaucoma.

CONFLICT OF INTEREST: None

FUNDING SOURCES: None

REFERENCES

- Jonas JB, Aung T, Bourne RR, Bron AM, Ritch R, Panda-Jonas S. Glaucoma—Authors reply. *Lancet*. 2018 Feb 24; 391(10122):740-45.
- Bickett AK, Le JT, Azuara-Blanco A, Gazzard G, Wormald R, Bunce C, et al. Minimally invasive glaucoma surgical techniques for open-angle glaucoma: An overview of 1;139 (9):983-9.
- Allison K, Patel D, Alabi O. Epidemiology of glaucoma: the past, present, and predictions for the future. *Cureus*. 2020 Nov 24; 12(11) 1-9.
- Sarfraz MH, Mehboob MA, ul Haq RI. Correlation between central corneal thickness and visual field defects, cup to disc ratio and retinal nerve fiber layer thickness in primary open angle glaucoma patients. *Pak. J. Med. Sci.* 2017 Jan; 33(1):132.
- El Bastay A, Gaber R, Elmaria A, Sabry M, Hussein TR. Correlation Between Changes in Lamina Cribrosa Structure and Visual Field in Primary Open-Angle Glaucoma. *Clin Ophthalmol*. 2021; 15: 4715- 21.
- Saba A, Usmani A, Islam QU, Assad T. Unfolding the enigma of lamina cribrosa morphometry and its association with glaucoma. *Pak. J. Med. Sci.* 2019 Nov; 35(6):1730-35.
- Wanichwecharungruang B, Kongthaworn A, Wagner D, Ruamviboonsuk P, Seresirikachorn K. Comparative Study of Lamina Cribrosa Thickness Between Primary Angle-Closure and Primary Open-Angle Glaucoma. *Clin Ophthalmol*. 2021;15: 697-705.
- Kim, J. A., Kim, T. W., Weinreb, R. N., Lee, E. J., Girard, M. J., Mari, J. M. Lamina cribrosa morphology predicts progressive retinal nerve fiber layer loss in eyes with suspected glaucoma. *Sci. Rep.* 2018; 8(1), 738-49. <https://www.nature.com/articles/s41598-017-17843-8>
- Kim YW, Jeoung JW, Girard MJ, Mari JM, Park KH, Kim DM. Clinical assessment of lamina cribrosa curvature in eyes with primary open-angle glaucoma. *PLoS one*. 2016. 11 (3), 1-15.
- Naz AS, Qamar A, Haque SU, Zaman Y, Faheem F. Association of lamina cribrosa morphometry with retinal nerve fiber layer loss and visual field defects in primary open angle glaucoma. *Pak. J. Med. Sci.* 2020 Mar; 36 (3): 521-25.
- McKean-Cowdin R, Varma R, Wu J, Hays R D, Azen S P. LALES. Severity of visual field loss and health-related quality of life. *Am J Ophthalmol*. 2017; 143(6), 1013-1023. Brusini P. Global Glaucoma Staging System (GGSS): A New Method to Simultaneously Assess the Severity of both Functional and Structural Damage in Glaucoma. *J. Clin. Med.* 2021 Sep 26; 10(19):4414-21.
- Parikh R, Kitmarong N, Jonas JB, Parikh SR, Thomas R. Optic disc morphology in primary open-angle glaucoma versus primary angle-closure glaucoma in South India. *Indian J. Ophthalmol*. 2021 Jul; 69 (7):1833-40.
- Xu X, Guan Y, Li J, Ma Z, Zhang L, Li L. Automatic glaucoma detection based on transfer induced attention network. *Biomed. Eng. Online*. 2021 Dec; 20(1):1-9.
- Chen A, Cheng YC, Lai HY, Lin PW, Wu PC, Kuo MT, et al. The severity of visual field defect and the defective angles of localized retinal nerve fiber layer using a novel approach. *J*

- Formos Med Assoc. 2021 Dec 1;120 (12):2153-9.
15. Tong YX, Zhang XY, He Y, Chen ZL, Jiang B. Optical coherence tomography evaluation of retinal nerve fiber layer thickness in non-arteritic anterior ischemic optic neuropathy and primary open angle glaucoma: a systematic review and Meta-analysis. *Int. J. Ophthalmol.* 2022; 15(8):1370-9.
 16. Ha A, Kim TJ, Lee WJ, Kim DM, Jeoung JW, Kim YK, et al. Quantitative analysis of retinal nerve fiber layer defect in early open-angle glaucoma with normal intraocular pressure. *Jpn. J. Ophthalmol.* 2020 May; 64 (3):278-84.
 17. Bhat KS, Reddy MV, Pai V. Correlation of retinal nerve fiber layer thickness with perimetric staging in primary open-angle glaucoma—A cross-sectional study. *Oman J Ophthalmol.* 2022 Jan 1;15 (1):36-41.
 18. Lee EJ, Kim TW, Kim H, Lee SH, Girard MJ, Mari JM. Comparison between lamina cribrosa depth and curvature as a predictor of progressive retinal nerve fiber layer thinning in primary open-angle glaucoma. *Ophthalmol. Glaucoma.* 2018 Jul 1; 1(1):44-51.

CONTRIBUTORS

1. **Ayesha Saba Naz** – Concept & Design; Data Analysis/Interpretation; Drafting Manuscript; Critical Revision; Supervision
2. **Aisha Qamar** – Supervision; Final Approval
3. **Ambreen Surti** – Data Acquisition; Data Analysis/Interpretation
4. **Sehrish Shafique** – Data Acquisition; Data Analysis/Interpretation
5. **Yasmeen Mahar** – Data Analysis/Interpretation; Drafting Manuscript
6. **Yawar Zaman** – Supervision; Final Approval
7. **Nasim Marvi** – Data Acquisition; Data Analysis/Interpretation

