

## PARADOXICAL HYPERTRICHOSIS AFTER LASER THERAPY

Naseem Ullah<sup>1</sup>, Abdur Rahim Khan<sup>2</sup>, Shahida Naz<sup>3</sup>, Kalsoom Aslam<sup>4</sup>, Muhammad Suhail<sup>5</sup>, Sadiq Khan<sup>6</sup>

**ABSTRACT:****OBJECTIVES:**

*In numerous cultures, unwanted hair is considered a common aesthetic problem. For hair removal, the use of lasers is a common medical procedure that is comparatively safe and has few side effects. Paradoxical hypertrichosis has been reported rarely in previous studies. The aim of this study was to find out the frequency of paradoxical hypertrichosis after laser treatment.*

**METHODOLOGY:**

*This cross sectional study was done for a period of one year from January 2020 to January 2021. This study was conducted at Al-Shifa Clinic and Skin Aesthetic, Nowshera, Khyber Pakhtunkhwa. All those patients who go-through the laser hair removal were included in the study. Diode laser with 808nm wavelength was used. All the patients were observed for paradoxical hypertrichosis after laser treatment.*

**RESULTS:**

*Total 140 patients underwent laser hair removal during a one-year study. There were 120 females and 20 male in our study. The mean age of male was 28±1.2 while the mean age of females was 26±1.4. Amongst 140 patients, the overall prevalence of paradoxical hypertrichosis after laser treatment was 7.8% (n=11). This side effect was observed dominantly on the neck and face. Skin phototype III and IV were observed with this side effect.*

**CONCLUSION:**

*Our research study concludes that paradoxical hypertrichosis occurs rarely after laser therapy. Study with high sample size and risk factors should be done for better understanding.*

**KEYWORDS:** Paradoxical Hypertrichosis, Laser Therapy, Diode Laser, Risk Factors

**How to cite this article:**

Ullah N, Khan AR, Naz S, Aslam K, Suhail M, Khan S. Paradoxical Hypertrichosis after Laser Therapy. J Gandhara Med Dent Sci. 2021;8(4): 55-60  
<https://doi.org/10.37762/jgm.8-4.260>

**Correspondence:**

<sup>3</sup>Shahida Naz, Senior Registrar, PIMS Hayatabad Peshawar

Contact: 03335125436

Email: [dr.shahidajalil@gmail.com](mailto:dr.shahidajalil@gmail.com)

<sup>1</sup>Senior registrar, Qazi Hussain Ahmad Complex Nowshera.

<sup>2</sup>Associate Professor Dermatology Unit MTI/Hayatabad Medical Complex Peshawar.

<sup>4</sup>Senior registrar, Kuwait teaching hospital Peshawar.

<sup>5</sup>District specialist Mian Rashid Hospital Pabbi, Nowshera.

<sup>6</sup>Assistant professor Gajju Khan medical college BMC Swabi

**INTRODUCTION:**

In numerous cultures, unwanted hair is considered a common aesthetic problem. Psychological problems like depression and anxiety are caused by hirsutism and hypertrichosis. Quality of life can be improved by removing hair using various methods like shaving, waxing, plucking, chemical depilatories and electrolysis<sup>1</sup>. Unwanted hairs are only temporarily removed by majority of these techniques, while unwanted hairs can be removed permanently by electrolysis. Electrolysis techniques are dependent on the operator and their efficacy is variable<sup>2,3</sup>.

Innovation for better treatment of hair removal is generated by the fact of unwanted hair on the face and other body parts as a common problem in all societies<sup>4</sup>. The clinical practice of hair removal by laser therapy was first approved by the US Food and Drug Administration (FDA) in 1996<sup>5</sup>. After this approval advances in laser technology occur in this field. To overcome this problem, many red and infrared laser and light sources were developed and distributed. For long-term removal of unwanted hair, laser therapy is the currently available efficient method. Many types of laser therapy are used and these include ruby laser (694 nm), alexandrite laser (755 nm), diode laser (800 nm), etc<sup>6</sup>. With the duration of pulse in the range of milli-second, melanin in the hair follicles is targeted<sup>7,8</sup>. On the basis of selective photo-thermo-lysis, in the shaft of hair melanin absorbs the light energy and converts them into thermal energy, which in turn results in damaging the structure of hair follicles. The hair follicles are only damaged by the short pulses of the thermal energy and the adjacent tissues are protected<sup>9,10</sup>. Wavelength, laser fluency, duration of pulse and size of spot are some of the laser irradiation factors that have been reported as follicle damage influence. On the other hand the factors of patients like hair growth cycle are still under study<sup>11</sup>. Hair removal by laser is safe with no or few side effects. Melanin causes damage to the epidermis hence melanin is responsible for these few side effects. In tanned and darker skin types, these side effects occur more as compared to other types of skin. The side effects include hypopigmentation, hyperpigmentation, formation of superficial crust or vesicles and scarring but these side effects are reduced to a larger extent by concurrent epidermal cooling. In nature, major side effects are transient but some studies reported permanent side effects that include scar formation and hypopigmentation<sup>12,13</sup>. After laser therapy, appearance of terminal hairs has been observed in areas where previously there were no hairs before laser therapy. Mainly it happens to the area near hair epilation and particularly hairs treated in vellus. Various names were proposed for this hair growth like terminal hair development, hair induction, terminalization and paradoxical effects<sup>14,15</sup>. In patients treated with laser for hair removal, paradoxical hypertrichosis is

rarely reported ranging from 0.6% to 10%<sup>16-19</sup>. Use of alexandrite and IPL devices mostly result in this side effect and surrounding area can also be affected<sup>18</sup>. The exact mechanism of this side effect is not known but however there are various theories regarding their mechanism. One of the theories proposed that new hair growth is stimulated by the laser, through dormant hair follicles synchronization into terminal anagen hair growth. Appearance of greater density of hair occurs as compared to previously asynchronous hair growth<sup>16</sup>. Terminal hairs from vellus hairs can be induced by suboptimal fluences according to another hypothesis<sup>19</sup>. Darker skin types (III-VI) are the major risk factor for this side effect. This complication commonly occurs in countries like the Mediterranean, Middle Eastern, Asian, and South Asian countries where the majority of people have dark, thick hair and underlying hormonal conditions. Hair growth will be ultimately reduced with continuous use of laser treatment in spite of initial hypertrichosis. Increase in density of hair, color change, coarseness or any combination of these in comparison with the basic photograph, having absence of known cause of hypertrichosis were defined as paradoxical hypertrichosis after laser therapy. In another previous study done by Hirsch and colleagues reported paradoxical hypertrichosis in 14 patients by using long-pulse 755-nm alexandrite laser<sup>20</sup>. Up till now various studies have been done on this but their prevalence is still not known exactly<sup>21,22</sup>. Laser therapy for hair removal is commonly used in Pakistan but up till now no study has been done on it. Therefore we piloted this study to determine the frequency of paradoxical hypertrichosis after laser treatment.

#### METHODOLOGY:

This cross sectional study was done for a period of one year from January 2020 to January 2021. This study was conducted at Al-Shifa Clinic and Skin Aesthetic, Nowshera, Khyber Pakhtunkhwa. The study approval was given by the research and ethical committee. Informed consent was signed from all the patients included in our research study. All those patients who go-through the laser hair removal were included in the study. Diode laser with 808nm wavelength was used. From all the patients complete history and clinical

examination was done. The criteria of inclusion for our study were patients of all ages and both the gender who visit the clinic for laser hair removal, while the exclusion criteria were all the patients with underlying problems like cancer and other hair problems. Well-trained dermatologists perform the procedure of laser hair removal from the face while from all parts of the body, the hair removal by laser was done by well-trained nurses under the supervision of a well-trained dermatologist. Increase in density of hair, color change, coarseness or any combination of these in comparison with the basic photograph, having absence of known cause of hypertrichosis were defined as paradoxical hypertrichosis after laser therapy. All the patients were observed for paradoxical hypertrichosis after laser treatment. During the mentioned time period, all patients who go through the laser therapies were contacted and patients with hypertrichosis were noted. For categorical data, frequency and percentages were reported. Data was entered and analyzed by using SPSS version 16.

**RESULTS:**

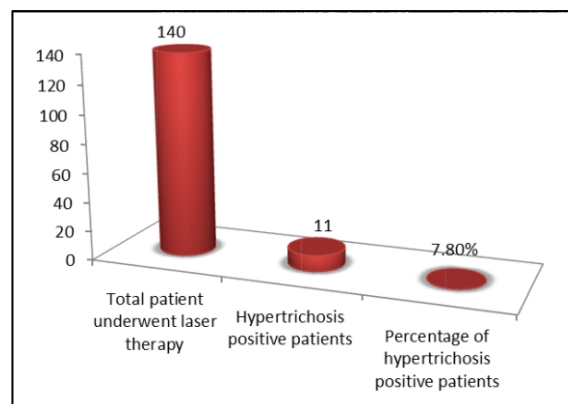
Total 140 patients underwent laser hair removal during a one-year study. There were 120 females and 20 male in our study (Table 1). The mean age of male was 28±1.2 while the mean age of female was 26±1.4 (Table 2). Amongst 140 patients, the overall prevalence of paradoxical hypertrichosis after laser treatment was 7.8% (n=11) as shown in Figure 1. Laser therapy was measured as the cause for hypertrichosis as it occurs on the site of laser therapy. In male no case of hypertrichosis was observed while all the 11 cases were observed in females. This side effect was observed dominantly on the neck and face. Amongst the 11 hypertrichosis patients, on neck and face, the hypertrichosis occurs in 4 and 7 patients, respectively. Skin phototype III and 1V were observed with this side effect. Amongst the 11 hypertrichosis patients, 6 patients have skin phototype 1V while 5 have skin phototype III (Table 3).

**Table 1: Gender Wise Distribution of Patients going through Laser Therapy**

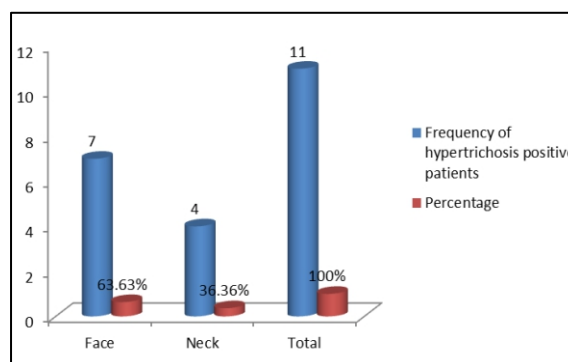
Gender	Frequency	Percentage
Male	20	14.29%
Female	120	85.71%
Total	140	100%

**Table 2: Age Wise Distribution of Patients who Underwent Laser Therapy**

Variable	Male Mean±SD	Female Mean±SD
Age (Year)	28±1.2	26±1.4



**Figure 1: Overall Prevalence of Hypertrichosis amongst Laser Therapy Patients**



**Figure 2: Comparative Prevalence of Hypertrichosis between Neck and Face**

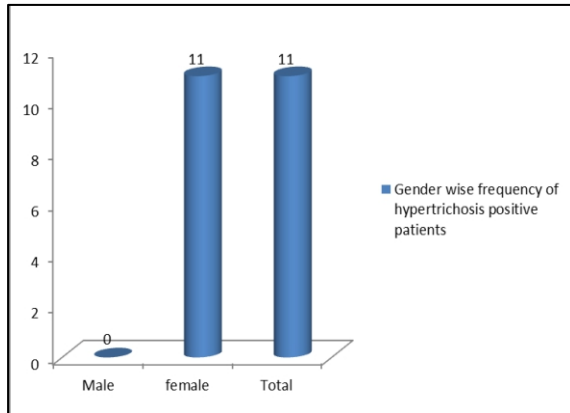


Figure 3: Comparative Prevalence of Hypertrichosis between Male and Female

Table 3: Comparative Prevalence of Hypertrichosis between Skin Phototype III and 1V

Skin Phototype	Frequency of Hypertrichosis Positive Patients	Percentage
III	5	45.46 %
1V	6	54.54 %
Total	11	100%

**DISCUSSION:**

Paradoxical hypertrichosis side effects of laser therapy are considered as recent side effects after the laser was approved as a medical device for hair removal by FDA. Paradoxical hypertrichosis has been reported rarely in previous studies. For the first time in 2002, hypertrichosis after laser treatment was reported by Morenos et al and Hirsch et al, respectively<sup>15-20</sup>. With age, an increase in hair from vellus to terminal occurs in the majority of the women. Terminal pigmented hairs are developed by about 25% women around their lips, areola and the area over lower abdomen. This increase in hairs occurs until menopause<sup>23,24</sup>. During gestation, all the hair follicles are formed and after birth, neogenesis does not occurs<sup>21</sup>, therefore the only way for induction of hair is transformation of local vellus hair follicles to terminal pigmented hair follicles. No previous study has been done on hypertrichosis after laser therapy in Pakistan. Therefore this study was carried out to determine the paradoxical hypertrichosis after

laser therapy. In our study, a total 140 patients underwent laser hair removal during a one-year study. There were 120 females and 20 male in our study. The ratio of female patients was higher as compared to male because in our country's culture, mostly male do not remove their hair. High female to male ratio was also observed in another study done by Gerhard Fierlbeck et al<sup>25</sup>. The mean age of male was 28±1.2 while the mean age of females was 26±1.4. Similar mean age was observed in study done by Abdul Majeed A et al<sup>16</sup>. As most of hair removal by laser therapy is done in the adult stage hence age cannot be used as a risk factor for paradoxical hypertrichosis. Amongst 140 patients, the overall prevalence of paradoxical hypertrichosis after laser treatment was 7.8% (n=11). Laser therapy was measured as the cause for hypertrichosis as it occurs on the site of laser therapy. In relation to the total number of the patients, numerous studies reported a very rare number of patients with hypertrichosis. In comparison to our study, lower frequency of hypertrichosis has been reported in previous studies and Abdul Majeed A et al<sup>16</sup> reported the frequency of hypertrichosis as 0.6%. Skin phototype III and 1V might be the possible reason for our high prevalence as compared to other studies because skin phototype III and 1V patients have a high chance of hair follicle transformation from vellus to terminal. In various previous studies done by physicians from countries such as Spain, Greece and Iran, the majority of the reports on paradoxical hypertrichosis have been published by them. The majority of the population in these countries have darker phototype skin<sup>14,15</sup>. In male no case of hypertrichosis was observed while all the 11 cases were observed in females. Our findings are consistent with Gerhard Fierlbeck et al, who reported no case of hypertrichosis in male and observed all the cases in female<sup>25</sup>. Gender cannot be considered as a risk factor because laser therapy for hair removal is mostly done by adult women. This side effect was observed dominantly on the neck and face. Amongst the 11 hypertrichosis patients, on neck and face, the hypertrichosis occurs in 4 and 7 patients, respectively. These findings are in accordance with the findings of other studies that reported the majority of the hypertrichosis cases on face and neck. These might be due to the fact

that the majority of the people remove their hairs from face and neck by laser therapy. Skin phototype III and 1V were observed with this side effect. Amongst the 11 hypertrichosis patients, 6 patients have skin phototype 1V while 5 have skin phototype III. These findings are in accordance with the reported studies who observed paradoxical hypertrichosis in skin phototype III and 1V<sup>25</sup>.

#### CONCLUSION:

Our research study concludes that paradoxical hypertrichosis occurs rarely after laser therapy. All the patients should be aware of the paradoxical hypertrichosis and it should be included in the consent form. Dark skin and suboptimal laser fluences might be considered as risk factors for paradoxical hypertrichosis especially for face and neck. Study with high sample size and risk factors should be done for better understanding.

**CONFLICT OF INTEREST:** None

**FUNDING SOURCES:** None

#### REFERENCES:

1. Bray FN, Falto-Aizpurua L, Griffith RD, Simmons B, Rajabi-Estarabadi A, Nouri K. Lasers for hair removal. *Pediatr Dermatol Surg.* 2019;273-87.
2. Zhang WR, Garrett GL, Arron ST, Garcia MM. Laser hair removal for genital gender affirming surgery. *Transl Androl Urol.* 2016;5(3):381.
3. Martella A, Raichi M. Photoepilation and skin photorejuvenation: an update. *Dermatol Rep.* 2017;9(1).
4. Tawfik A, Osman MA, Rashwan I. A novel treatment of acne keloidalis nuchae by long-pulsed alexandrite laser. *Dermatol Surg.* 2018;44(3):413-20.
5. Mallory SB. *An illustrated dictionary of dermatologic syndromes.* 2<sup>nd</sup> ed. London: Routledge; 2019.
6. Clatici VG, Voicu C, Barinova E, Mihai L, Tatu AL. Complications of laser hair removal-how we could reduce them?. *Dermatol Ther.* 2020;33(4):e13518.
7. Umar S. Selection criteria and techniques for improved cosmesis and predictable outcomes in laser hair removal treatment of acne keloidalis nuchae. *JAAD Case Rep.* 2019;5(6):529.
8. Bhat YJ, Bashir S, Nabi N, Hassan I. Laser treatment in hirsutism: an update. *Dermatol Pract Concept.* 2020;10(2).
9. Huang Y, Wu Z, Lui H, Zhao J, Xie S, Zeng H. Precise closure of single blood vessels via multiphoton absorption-based photothermolysis. *Sci Adv.* 2019;5(5):eaan9388.
10. Brown ER. *Fundamentals of Lasers and Light Devices in Dermatology.* In: Madan V, editor. *Practical Introduction to Laser Dermatology.* Springer, Cham; 2020. p. 1-52.
11. Ayatollahi A, Samadi A, Rajabi-Estarabadi A, Yadangi S, Nouri K, Firooz A. Comparison of efficacy and safety of a novel 755-nm diode laser with conventional 755-nm alexandrite laser in reduction of axillary hairs. *Lasers Med Sci.* 2020;35(2):373-8.
12. Abdul-Hussein AA, Razzaq SA, Shak HH. Effectiveness of diode laser versus intense pulsed light in hirsutism: a prospective and comparative study in Samawa city. *Int J Psychosoc Rehabil.* 2020;24(02).
13. Ghaderi R, Asghari M, Bakshshae M. Efficacy of intense pulsed light in hirsutism treatment: a clinical trial study. *J Surg Trauma.* 2018;6(3).
14. Town G, Bjerring P. Is paradoxical hair growth caused by low-level radiant exposure by home-use laser and intense pulsed light devices?. *J Cosmet Laser Ther.* 2016;18(6):355-62.
15. Fodor L, Bota O. Complications After IPL Treatment. In: Fodor L, Ullmann Y, editors. *Aesthetic Applications of Intense Pulsed Light.* Springer, Cham; 2020. p. 195-216.
16. Sánchez LC, Guillén BF, Carazo JL, Ferriols AP. Adverse cutaneous events after laser epilation in patients with photodermatosis. *Indian J Dermatol Venereol Leprol.* 2018;84(6):718-20.
17. Zarei M, Wikramanayake TC, Falto-Aizpurua L, Schachner LA, Jimenez JJ. Low level laser therapy and hair regrowth: an evidence-based review. *Lasers Med Sci.* 2016;31(2):363-71.

18. Schuler A, Veenstra J, Tisack A. Folliculitis induced by laser hair removal: proposed mechanism and treatment. *J Clin Aesthetic Dermatol.* 2020;13(5):34.
19. Dabek RJ, Roh DS, Ozdemir D, Austen Jr WG, Bojovic B. Fractional laser-assisted hair regrowth and microneedling for the treatment of alopecia areata: a review. *Cureus.* 2019;11(6).
20. Thomas MM, Houreld NN. The “in’s and outs” of laser hair removal: a mini review. *J Cosmet Laser Ther.* 2019;21(6):316-22.
21. Town G. Intense pulsed light (IPL) and laser hair reduction. *J Aesthetic Nurs.* 2019;8(7):328-33.
22. Eshleman EJ, LeBlanc M, Rokoff LB, Xu Y, Hu R, Lee K, et al. Occupational exposures and determinants of ultrafine particle concentrations during laser hair removal procedures. *Environ Health.* 2017;16(1):1-7.
23. Khan MA, Javed AA, Govindan KS, Rafiq S, Thomas K, Baker L, et al. Control of hair growth using long-pulsed alexandrite laser is an efficient and cost effective therapy for patients suffering from recurrent pilonidal disease. *Lasers Med Sci.* 2016;31(5):857-62.
24. Nistico SP, Del Duca E, Farnetani F, Guida S, Pellacani G, Rajabi-Estarabadi A, et al. Removal of unwanted hair: efficacy, tolerability, and safety of long-pulsed 755-nm alexandrite laser equipped with a sapphire handpiece. *Lasers Med Sci.* 2018;33(7):1479-83.
25. Honeybrook A, Crossing T, Bernstein E, Bloom J, Woodward J. Long-term outcome of a patient with paradoxical hypertrichosis after laser epilation. *J Cosmet Laser Ther.* 2018;20(3):179-83.

#### CONTRIBUTORS

1. **Naseem Ullah** - Concept & Design; Data Acquisition; Data Analysis/Interpretation; Drafting Manuscript
2. **Abdur Rahim Khan** - Data Analysis/Interpretation; Drafting Manuscript
3. **Shahida Naz** - Concept & Design; Drafting Manuscript; Supervision; Final Approval
4. **Kalsoom Aslam** - Concept & Design; Drafting Manuscript
5. **Muhammad Suhail** - Data Acquisition; Data Analysis/Interpretation
6. **Sadiq Khan** - Drafting Manuscript; Critical Revision



**LICENSE:** JGMDS publishes its articles under a Creative Commons Attribution Non-Commercial Share-Alike license (CC-BY-NC-SA 4.0).  
**COPYRIGHTS:** Authors retain the rights without any restrictions to freely download, print, share and disseminate the article for any lawful purpose. It includes scholarly networks such as Research Gate, Google Scholar, LinkedIn, Academia.edu, Twitter, and other academic or professional networking sites.