

OUTCOME COMPARISON OF ENDOSCOPIC (ENDONASAL TRANS-SPHENOIDAL) REPAIRS OF CSF LEAK VS. TRANSCRANIAL APPROACH

Mehran Ali¹, Naseer Hassan², Mansoor Ali³, Hamayun Tahir⁴, Samir Khan Kabir⁵, Raza Hassan⁶

ABSTRACT:

OBJECTIVES:

To compare the effectiveness of Endoscopic (endonasal transsphenoidal) repair of CSF leak with transcranial approach in terms of post-operative complications.

METHODOLOGY:

This study was conducted in the Department of Neurosurgery, Lady Reading Hospital, Peshawar. Total of 40 patients diagnosed according to inclusion criteria were enrolled and were divided into two groups. One group was treated with endonasal trans-sphenoidal repair, and another was treated with a trans-cranial approach. All patients were followed for 1 year.

RESULTS:

The mean age of enrolled patients was 35.4±11.6 years. There were 62.5% male and 37.5% female. In the endoscopic group the recurrence rate was observed in 3 (15%) of the patients while in the trans-cranial group the recurrence rate was observed in 2 (10%) of the patients. The overall recurrence and success rate was 8% and 92% respectively. About 4 patients developed an infection, which was treated successfully.

CONCLUSION:

It is concluded that the endoscopic approach is safe and effective. The endoscopic approach should be considered as standard procedure for treatment.

KEYWORDS: CSF Leak, Tran-Sphenoidal, Trans-Cranial Approach

How to cite this article:

Ali M, Hassan N, Ali M, Tahir H, Kabir SK, Hassan R. Outcome Comparison of Endoscopic (Endonasal Trans-Sphenoidal) Repairs of CSF Leak vs Transcranial Approach. J Gandhara Med Dent Sci. 2022;9(1): 39-43
<https://doi.org/10.37762/jgmids.9-1.246>

Correspondence:

¹Naseer Hassan, Assistant Professor, Department of Neurosurgery, Nowshera Medical College, Nowshera.

☎: +92-321-9119080

✉: dmaseerhassan@gmail.com

²Senior Registrar, Department of Neurosurgery, Nowshera Medical College, Nowshera.

³Senior Registrar, Department of Neurosurgery, Nowshera Medical College, Nowshera.

⁴Senior Registrar, Department of Neurosurgery, Nowshera Medical College, Nowshera

⁵Assistant Professor, Department of Orthopedics, Hayatabad Medical Complex, Peshawar

⁶Senior Clinical Fellow, Trauma and Orthopedics, Royal Free London Hospital, London

INTRODUCTION:

The dura matter, a membrane, encloses the spinal cord and brain. Damage to this membrane causes egress of cerebrospinal fluid (CSF) from the brain and spinal cord. This leakage minimizes the pressure around the brain and spinal cord. About 140-270 ml of CSF are found in the adult¹. Annually about 10% of patients develop meningitis with CSF fistulas². CSF plays an important role in the protection of the brain and untreated leakage can lead to life-threatening disorders³. CSF is a colorless fluid so its detection in humans is very

challenging because sometimes it is mixed with other fluids such as serum. Sometimes its symptoms such as headache, tinnitus, and nasal drainage are also misdiagnosed^{4,6}. For management of CSF leakage different tests are used such as Halo sign and Reservoir sign and β -2 transferrin. Among these procedures, β -2 transferrin is a specially designed biochemical assay for the detection of CSF leakage^{5,7,8}. Approximately 90% of CSF leaks restore naturally and do not need any surgical procedure⁹. Two treatment techniques are used for CSF leakage, (a) medical (b) surgical. When conservative treatment techniques fail, then we use surgical procedures for CSF leaks: transcranial and endoscopic. As compared to trans-sphenoidal approach, the Trans-cranial approach has a greater rate of post-op complications. Postoperative complications are of major concern in-patient undergoing these approaches. Trans-cranial approach carries 3-4% risks of seizures because of brain retraction. Patients undergoing the trans-cranial approach were advised to take care and not drive a car for about one year. Trans-sphenoidal repair of CSF leak needs endoscope through the nasal cavity, which shows us a clear and magnified image. If a clear image is not shown, then Fluorescein dye is used preoperatively to visualize. Fluorescein dye gives green yellow color to CSF leak¹⁰.

METHODOLOGY:

This comparative, experimental randomized trial study was conducted at Neurosurgery Department, Lady Reading Hospital, Peshawar. The sample size was 40, equally divided into two groups (20 patients in each group) by keeping the power of study equal to 80% by using the following formula:

$$n = \frac{Z_{\beta}^2 [p_1(1 - p_1) + p_2(1 - p_2)]}{(p_2 - p_1)^2}$$

Duration of the study was 6 months (March 2020–August 2020). Patients were recruited by non-probability and purposive sampling techniques. Those patients who were diagnosed as persistent CSF leak, having traumatic and spontaneous or iatrogenic CSF leak, age group 18-60 years and both gender (male and female) were included in the study. Those patients suffering from chronic renal failure and chronic liver disease and suffering from active neurological diseases like wound infection and meningitis were excluded. According to inclusion criteria, totally 40 patients diagnosed as persistent CSF leak, having traumatic and

spontaneous or iatrogenic CSF leak was enrolled. Approval was obtained from the College of Physicians and Surgeons Pakistan (CPSP) and the hospital's ethical committee before starting the study. The enrolled patients were divided into two groups by a closed envelope method. One group was treated with endonasal trans-sphenoidal repair and another was treated with a trans-cranial approach. All patients were followed for 1 year.

Endoscopic Approach:

The Endonasal Trans sphenoidal route has become the standard endoscopic procedure for surgical treatment as compared to transcranial procedures. Half of the patients were treated with endonasal trans-sphenoidal repair. The enrolled patients were given systematic antibiotics and were operated under general anesthesia. The face and nasal cavity of the operated individual were properly washed. The head of the patient was slightly extended and turned toward the side of the operating surgeon. A universal endoscope having 6.5 mm outer diameter of the operating sheath and 0-degree telescope were used. A TV monitor and camera were added to the endoscope for the purpose of visual control. Prior to the introduction into the nasal cavity, a solution (adrenaline in saline) soaked cottonoids were kept for 3-5 minutes for hemostasis. The working sheath and telescope were introduced under direct visualization. The remaining procedure was performed according to protocol.

Transcranial Approach:

Transcranial Approach is an important procedure for CSF leak and is carried out throughout the world recently. In this study half of the enrolled patients were treated with transcranial procedure. Transcranial procedure is dependent on the fracture type, volume and site of the leak. An open transcranial approach will help in the clear visualization of the dural tear. In case, if the reconstruction of the dura matter is not possible then dural replacements (fascia lata of the thigh, pericranial graft, temporalis muscle fascia, etc.) can be done. The selection of dural replacements material depends on the length, site and availability of the material. By using the SPSS version 23.0, all the collected data were analyzed. Descriptive statistics was used to calculate mean±standard deviation for quantitative variables i.e. age and length of hospital stays. Frequency and percentages were presented for the qualitative variable i.e. gender, CSF leak and wound infection. Qualitative data was analyzed by using the Chi square test, keeping P-value ≤ 0.05 .

RESULTS:

All of the 40 enrolled patients fulfilling the inclusion criteria were studied for one year after treatment. Out of total patients, 62.5% were male and 37.5% were female with mean age of 35.4±11.6. Overall success rate was 88.9% and recurrence rate was 12%. Association between recurrence and gender was not significant (P-value 0.137) (Table 3). Association between Infection and gender was not significant (P-value 1.00) (Table 4). Association between recurrence and treatment was not significant (P-value 1.0) (Table 5). There was non-significant association between treatment and infection (P-value 1.00) (Table 6).

Table 1: Demographic Data of Patients (n=40)

Variable	Frequency	Percentage
Gender		
Male	25	62.5
Female	15	37.5
	Mean	SD
Age	35.4	11.6

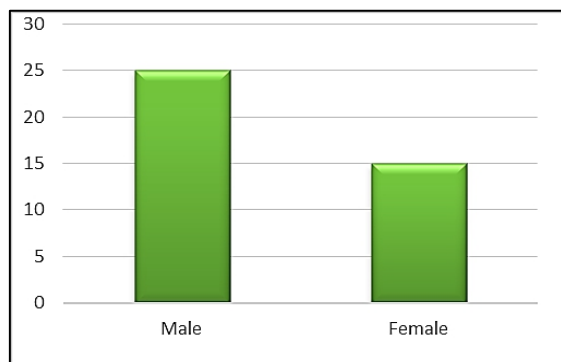


Figure 1: Graphical Representation on the Basis of Gender

Table 2: Comparison of Patients According to Sex and Treatment (n=40)

Gender	Endoscopic	Transcranial	Total
Male	13 (52%)	12 (48%)	25
Female	7 (46.7%)	8 (53.3%)	15
Total	20	20	40

Table 3: Comparison According to Sex and Recurrence (n=40)

Gender	Recurrence		Total
	No	Yes	
Male	23 (92%)	2 (8%)	25
Female	12 (80%)	3 (20%)	15
Total	35 (88%)	5 (12%)	40

Chi square test was applied (P-value 0.137)

Table 4: Comparison According to Sex and Infection (n=40)

Gender	Infection		Total
	No	Yes	
Male	22 (88%)	3 (12%)	25
Female	14 (93.3%)	1 (6.7%)	15
Total	36	4	40

Chi square test was applied (P-value 1.00)

Table 5: Comparison According to Treatment and Recurrence (n=40)

Treatment	Recurrence		Total
	No	Yes	
Endoscopic	17 (85%)	3 (15%)	20
Transcranial	18 (90%)	2 (10%)	20
Total	35	5	40

Chi square test was applied (P-value 1.00)

Table 6: Comparison According to Treatment and Infection (n=40)

Treatment	Infection		Total
	No	Yes	
Endoscopic	18 (90.0%)	2 (10.0%)	20
Transcranial	18 (90%)	2 (10%)	20
Total	36	4	40

Chi square test was applied (P-value 1.00)

DISCUSSION:

The CSF is produced by the choroid plexuses of the lateral and 4th ventricles from arterial blood plus small amounts by ependymal cells. About 140-270 ml of CSF are found in adults with a per minute production rate of 0.2-0.7 ml. CSF rhinorrhea is nutrient-rich fluid that flows around the brain and spinal cord into the nose. It can be divided into traumatic and non-traumatic.

With the development in the medical field such as the progress in endoscopic repair of CSF fistula, the cases have been significantly reduced for spontaneous leaks. But still conservative procedures have been used as a first line management for such cases. Surgical procedure is the last option in patients, which fails on conservative management. Extracranial procedure is safer than intracranial procedure with less complication so during the last 25 year, mostly extracranial procedure is used for the treatment of CSF rhinorrhea^{11,12}. CSF leak cases are very common all over the world and are one of the commonest causes of bed occupancy. In developing countries, like in Pakistan, the hospital is overburdened. As compared to trans-cranial

procedure the time duration of endoscopic procedure is short, about 2 hours. Therefore, we performed this research study to evaluate that the outcome between both procedures is the same.

In this study about 62.5% patients were male and 37.5% were female. Out of total males 52% and 48% were treated through endoscopy and Transcranial procedure respectively. Out of total females 80% and 20% were treated through endoscopy and trans-cranial procedure respectively. This study is similar to a study conducted by Ishfaq Ahmed Simair et al, at the Department of Neurosurgery, Lahore General Hospital⁹. Previously in a study the recurrence of CSF leak was observed in only 7.5% and overall success rate was 92.5%,⁹ and in this study the recurrence rate was 8.0% and overall success rate was 92%. The same success rate of about 94.5% with a single endoscopic procedure was also found by Stammberger et al,¹³ and other researchers^{14,15}. In the endoscopic procedure, 3 (15%) patients were observed with recurrences and two patients (10%) among the trans-cranial approach were observed with recurrence. Initially the success rate was 85.7% that later on reached 100%¹⁶⁻¹⁸. An endoscopic procedure makes available an effective means to repair anterior and middle cranial fossa skull base defects. Some factors are linked with the failure of an endoscopic procedure which include failure to find the bone defect, displacement of the graft, insufficient graft's length, incomplete application of the graft to the bone defect of the skull, failure of the patient to obey with postoperative instructions and poor healing of the wound. In this study overall 4 patients got infection, 3 male and 1 female. In comparison, according to treatment and infection, the p-value (1.0) was insignificant.

CONCLUSION:

It is concluded from this study that as compared to open surgical procedures the success rate of endoscopic repair is high with less morbidity and lower complication rate. It is recommended that being safe and effective, the endoscopic procedure should be considered as standard procedure for treatment.

CONFLICT OF INTEREST: None

FUNDING SOURCES: None

REFERENCES:

1. LeBras M, Chow I, Mabasa VH, Ensom MH. Systematic review of efficacy, pharmacokinetics, and administration of intraventricular aminoglycosides in adults. *Neurocrit Care*. 2016;25(3):492-507.
2. Christoforidou A, Tsitsopoulos P, Selviaridis P, Vital V, Constantinidis J. Endonasal endoscopic repair of cerebrospinal fluid leaks versus craniotomy: comparison of the outcomes. *Hippokratia*. 2016;20(4):299.
3. Zada G, Lopes MBS, Mukundan S, Laws E. Spontaneous, Traumatic, and Postoperative CSF Rhinorrhea. In: Zada G, Lopes M, Mukundan Jr S, Laws Jr E, editors. *Atlas of Sellar and Parasellar Lesions*. Switzerland: Springer, Cham; 2016. p. 517-23.
4. El-Fiky L, Kotb A, Mostafa BE. A unified management for spontaneous CSF leak. *Int J Otolaryngol Head Neck Surg*. 2015;4(02):141.
5. Oh J, Kwon S-J, Dordick JS, Sonstein WJ, Linhardt RJ, Kim M-G. Determination of cerebrospinal fluid leakage by selective deletion of transferrin glycoform using an immunochromatographic assay. *Theranostics*. 2019;9(14):4182.
6. Oh JW, Kim SH, Whang K. Traumatic cerebrospinal fluid leak: diagnosis and management. *Korean J Neurotrauma*. 2017;13(2):63-7.
7. Lipschitz N, Hazenfield JM, Breen JT, Samy RN. Laboratory testing and imaging in the evaluation of cranial cerebrospinal fluid leaks and encephaloceles. *Curr Opin Otolaryngol Head Neck Surg*. 2019;27(5):339-43.
8. Carey-IV PH, Yang J, Ren F, Liao YT, Chang CW, Lin J, et al. Fast cerebrospinal fluid detection using inexpensive modular packaging with disposable testing strips. *J Electrochem Soc*. 2019;166(8):B708.
9. Simair IA, Ali J, Khattak A, Qureshi A, Salah-ud-Din T. Outcome comparison of endoscopic (endonasal trans-sphenoidal) repairs of CSS leak vs. transcranial approach. *Pak J Neurol Surg*. 2021;25(1):18-28.
10. Hashemi Jazi S, Amini Z, Saboori M, Raisi M. Preoperative topical intranasal fluorescein in diagnosis of cerebrospinal fluid rhinorrhea. *Arch Trauma Res*. 2018;7(4):146-9.

11. Kreatsoulas DC, Shah VS, Otto BA, Carrau RL, Prevedello DM, Hardesty DA. Surgical outcomes of the endonasal endoscopic approach within a standardized management protocol for repair of spontaneous cerebrospinal fluid rhinorrhea. *J Neurosurg.* 2020;134(3):780-6.
12. Zhu ZJ, Cheng L, Yang J. Transnasal endoscopic repair of adult spontaneous cerebrospinal fluid rhinorrhea with assistance of computer-assisted navigation system: an analysis of 21 cases. *Eur Arch Oto-Rhino-Laryngol.* 2019;276(10):2835-41.
13. Tomazic PV, Stammberger H. Spontaneous CSF-leaks and meningoencephaloceles in sphenoid sinus by persisting Sternberg's canal. *Rhinology.* 2019;47(4):369.
14. Marinho R, Sousa M, Machado F, Fonseca S, Guedes L. Cerebrospinal fluid cutaneous fistula after neuraxial anesthesia: an effective treatment approach. *Scand J Pain.* 2018;18(4):739-41.
15. Patel K, Memon Z, Prince A, Park C, Sajan A, Ilyas N. Streptococcus Oralis meningitis from right sphenoid Meningoencephalocele and cerebrospinal fluid leak. *BMC Infect Dis.* 2019;19(1):1-4.
16. Smaija MS, Majeed A, Farid-Ullah HM. To determine frequency of Cerebrospinal Fluid (CSF) Rhinorrhoea after Trans-sphenoidal (TSS) surgery. *Pak J Neurol Surg.* 2015;19(4):225-9.
17. Mathias T, Levy J, Fatakia A, McCoul ED. Contemporary approach to the diagnosis and management of cerebrospinal fluid rhinorrhea. *Ochsner J.* 2016;16(2):136-42.
18. Shah N, Rao M. Analysis of various factors and techniques to improve outcome of surgical management of 243 cases of CSF rhinorrhea. *Indian J Otolaryngol Head Neck Surg.* 2019;71(2):201-5.

CONTRIBUTORS

1. **Mehran Ali** - Concept & Design; Critical Revision
2. **Naseer Hassan** - Data Acquisition; Supervision
3. **Mansoor Ali** - Critical Revision
4. **Hamayun Tahir** - Data Analysis/Interpretation; Drafting Manuscript
5. **Samir Khan Kabir** - Drafting Manuscript
6. **Raza Hassan** - Data Analysis/Interpretation; Drafting Manuscript



LICENSE: JGMDS publishes its articles under a Creative Commons Attribution Non-Commercial Share-Alike license (CC-BY-NC-SA 4.0).
COPYRIGHTS: Authors retain the rights without any restrictions to freely download, print, share and disseminate the article for any lawful purpose. It includes scholarly networks such as Research Gate, Google Scholar, LinkedIn, Academia.edu, Twitter, and other academic or professional networking sites.